

# Cutaneous Tuberculosis

## Leprosy

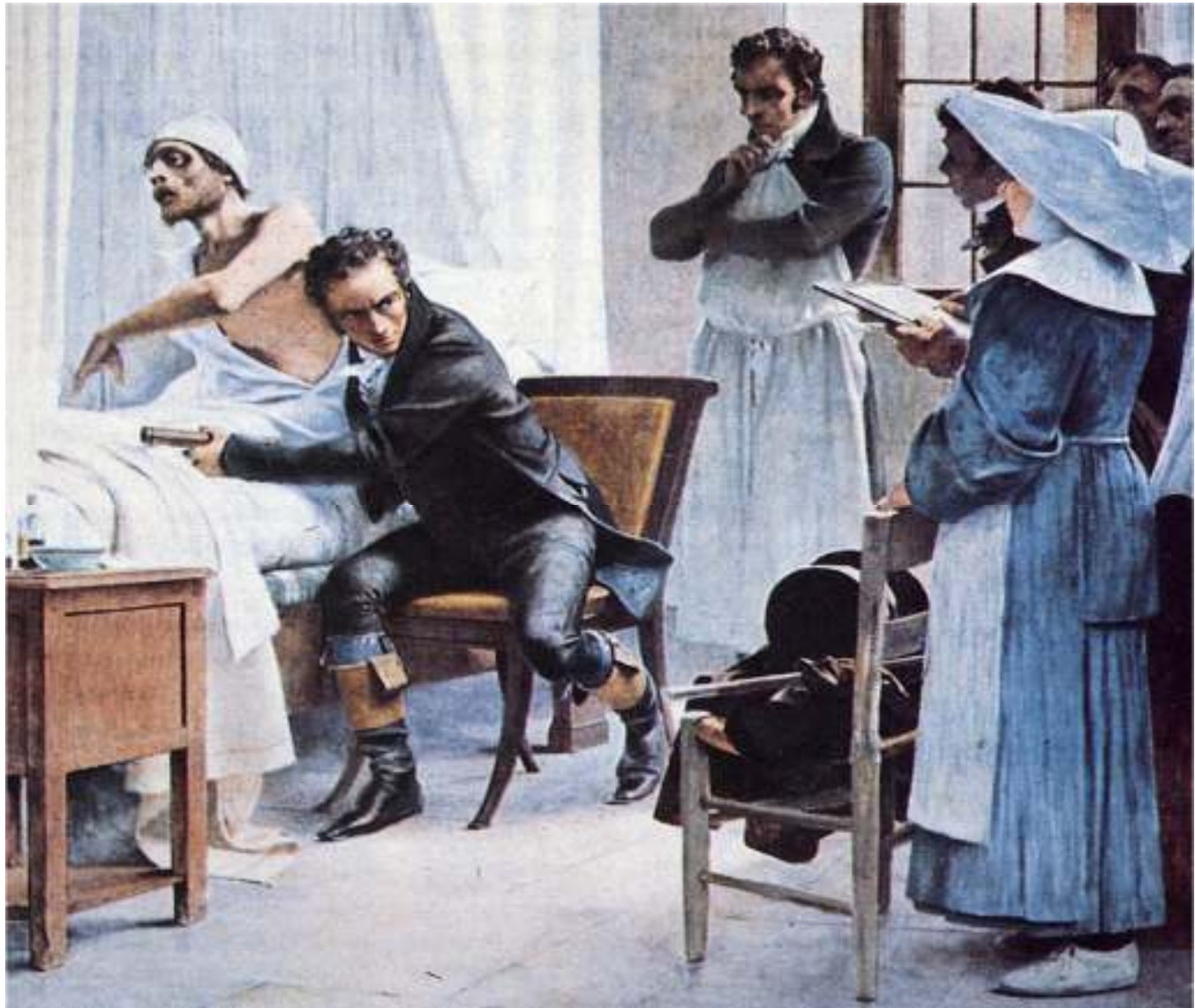Mircea Betiu

# *Mycobacterium*

- There are approximately 30 species of *Mycobacterium* that cause disease in humans.
- The primary culprits include *M. tuberculosis* complex, *M. leprae*, and atypical mycobacteria
- *M. tuberculosis* complex include:  
*M.tuberculosis, M.bovis, and M.africanum.*

# Definition

- Tuberculosis is a systemic infectious disease that can affect any organ system, including the skin
- Cutaneous tuberculosis (CT) has a broad clinical spectrum depending on the route of infection, virulence of the organism, and immune status of the host



- 1826, *René Laennec*, „prosector's wart”, first clinical description

# First histopathology



Rudolf Virchow  
(1821—1902)



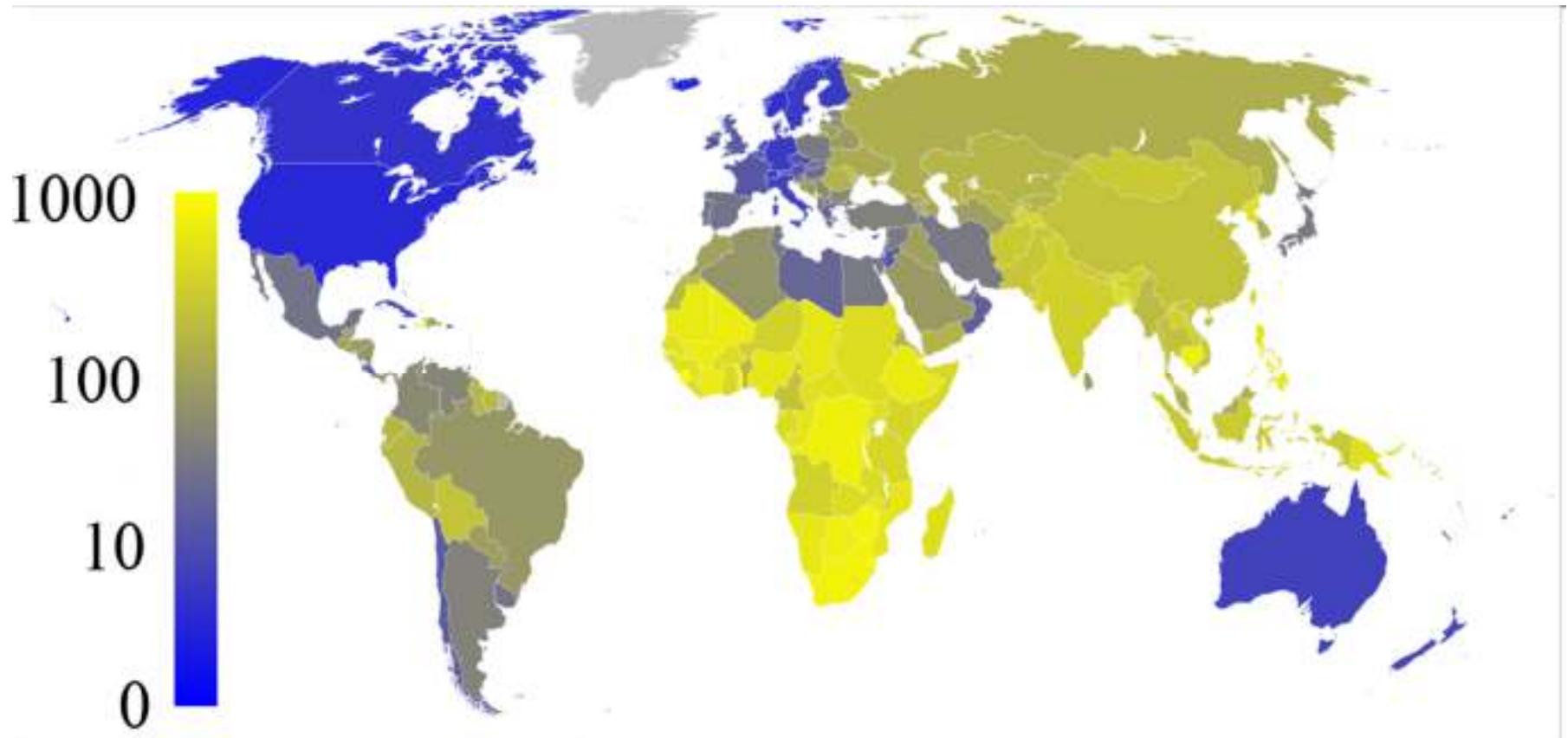
Carl von Rokitansky  
(1804-1878)

# First microbiology



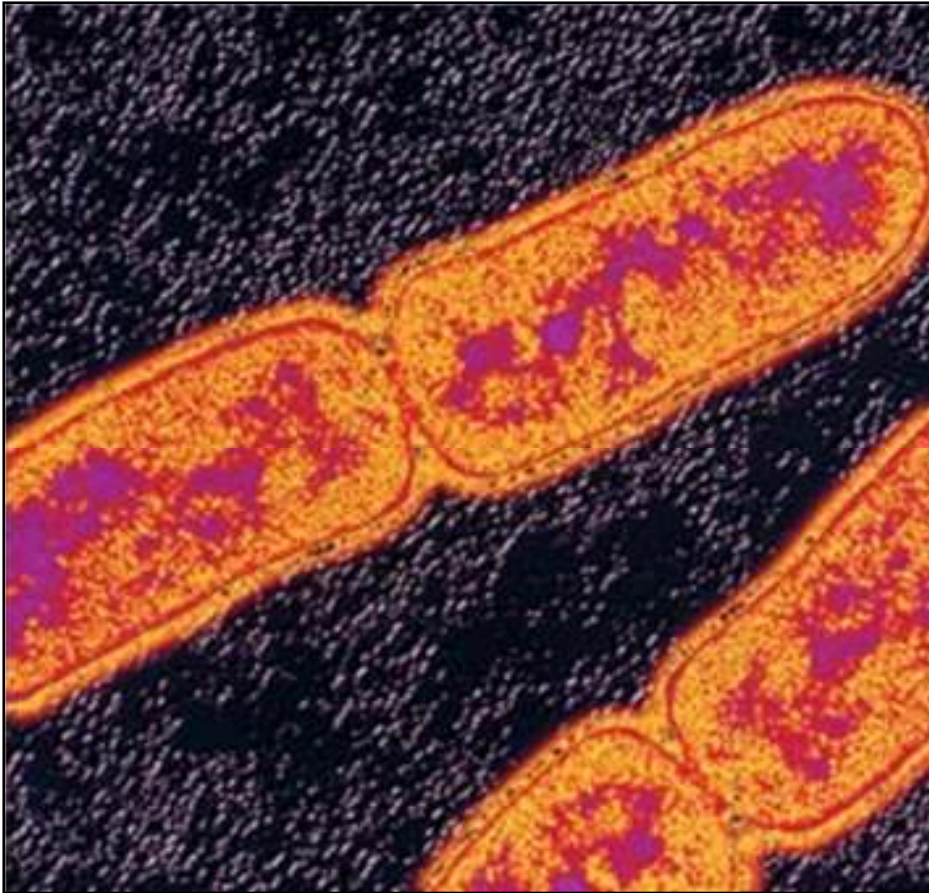
- *Robert Koch* in 1882 discovered the bacillus
- 1905, Nobel prize for medicine

## Epidemiology 2007



- 8-9 mln. new cases per year, among them 7 mln contagious cases, annual mortality is 2-3 mln cases.
- Incidence 10-700 cases per 100,000 population.

## Koch bacillus



- 1-4 microns length and 0,2-0,6 microns thickness.
- No capsules or spores, non-motile, gram-positive.
- Intracellular, facultative aerob, slow growth and multiplication rate.
- Complex antigenic compound.



# Etiology

- The obligate human pathogenic mucobacteria: *M.tuberculosis*, *M.bovis* and, occasionally, bacillus Calmette-Guerin (BCG)
- These are acid-fast, weakly gram-positive, nonsporulating and nonmotile rods.

# Classification of CT

- **Exogenous:**
  - Primary inoculation tuberculosis
  - Tuberculosis verrucosa cutis
- **Endogenous:**
  - Scrofuloderma
  - Orificial tuberculosis
- **Hematogenous/lymphatic:**
  - Lupus vulgaris
  - Acute miliary tuberculosis
  - Tuberculides

# CLASIFICAREA TUBERCULOZEI CUTANATE (Wilkinson)

## A. TUBERCULOZE TIPICE SAU PROGRESIVE

*(CARE SUNT IDUSE DIRECT DE BK):*

### I. TUBERCULOZE PRIMARE:

- ȘANCRUL TUBERCULOS
- TUBERCULOZA VERUCOASĂ

### II. TUBERCULOZE SECUNDARE

- LUPUS VULGAR TUBERCULOS
- SCROFULODERMA (GOMA TUBERCULOASĂ)
- TUBERCULOZA MILIARĂ A FEȚEI

### III. TUBERCULOZE DE REINOCULARE

- ULCERUL TUBERCULOS
- TUBERCULOZA VEGETANTĂ

## B. TUBERCULOZE ATIPICE SAU TUBERCULIDE

*(SUNT REACȚII TOXICO-ALERGICE CUTANATE LA INFECTAREA CU BK, CARE ÎNSĂ ÎN ERUPȚII DE OBICEI NU ESTE DEPISTAT):*

### I. T. MICROPAPULOASE

- LICHEN SCROFULOSUS

### II. T. PUSTULOASE

- TUBERCULIDE PAPULO-NECROTICE

### III. T. NODULARE

- ERITEM INDURAT BAZIN
- TUBERCULIDE NODULARE ATIPICE

## Clasificarea tuberculozelor cutanate în dependență de încărcătura bacilară în leziuni

(Bravo FG, Gotuzzo E 2007)

- Formele multibacilare (depistarea agentului - obligatorie)
  - șancrul tuberculos,
  - scrofuloderma,
  - ulcerul tuberculos orificial,
  - goma tuberculoasă,
  - tuberculoza miliară acută.
- Formele paucibacilare (depistarea agentului este dificilă)
  - lupusul vulgar
  - tuberculoza verucoasă,
  - *tuberculidele* (prezența ADN-ului bacilar demonstrată prin PCR)
    - lichenul scrofulos,
    - tuberculoza papulo-necrotică,
    - eritemul indurat Bazin),

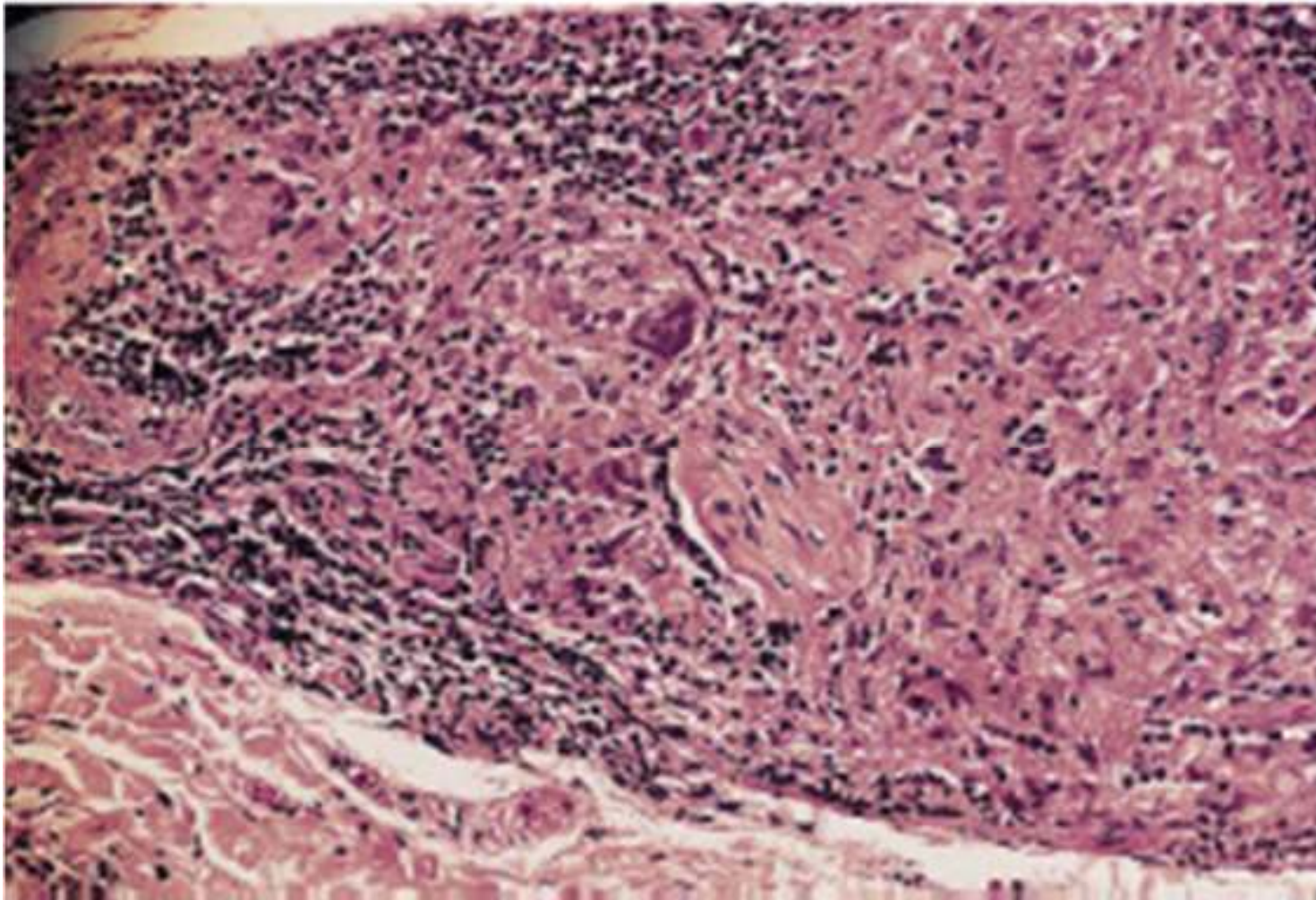
# Route of CT infection

- Exogenous infection is acquired from an outside source: primary inoculation tuberculosis as a primary infection in a non-immune host; tuberculosis verrucosa cutis as a secondary infection in an immune host
- Endogenous spread as organisms are passed from internal organ involvement: scrofuloderma by contiguous spread; orificial tuberculosis by autoinoculation
- Through hematogenous or lymphatic dissemination: lupus vulgaris and miliary tuberculosis.

# Histopathology

The **tubercle** is the histopathologic hallmark of tuberculosis; it consists of giant cells, epithelioid cells and may have varying amounts of caseation necrosis.

# TUBERCULOID GRANULOMA

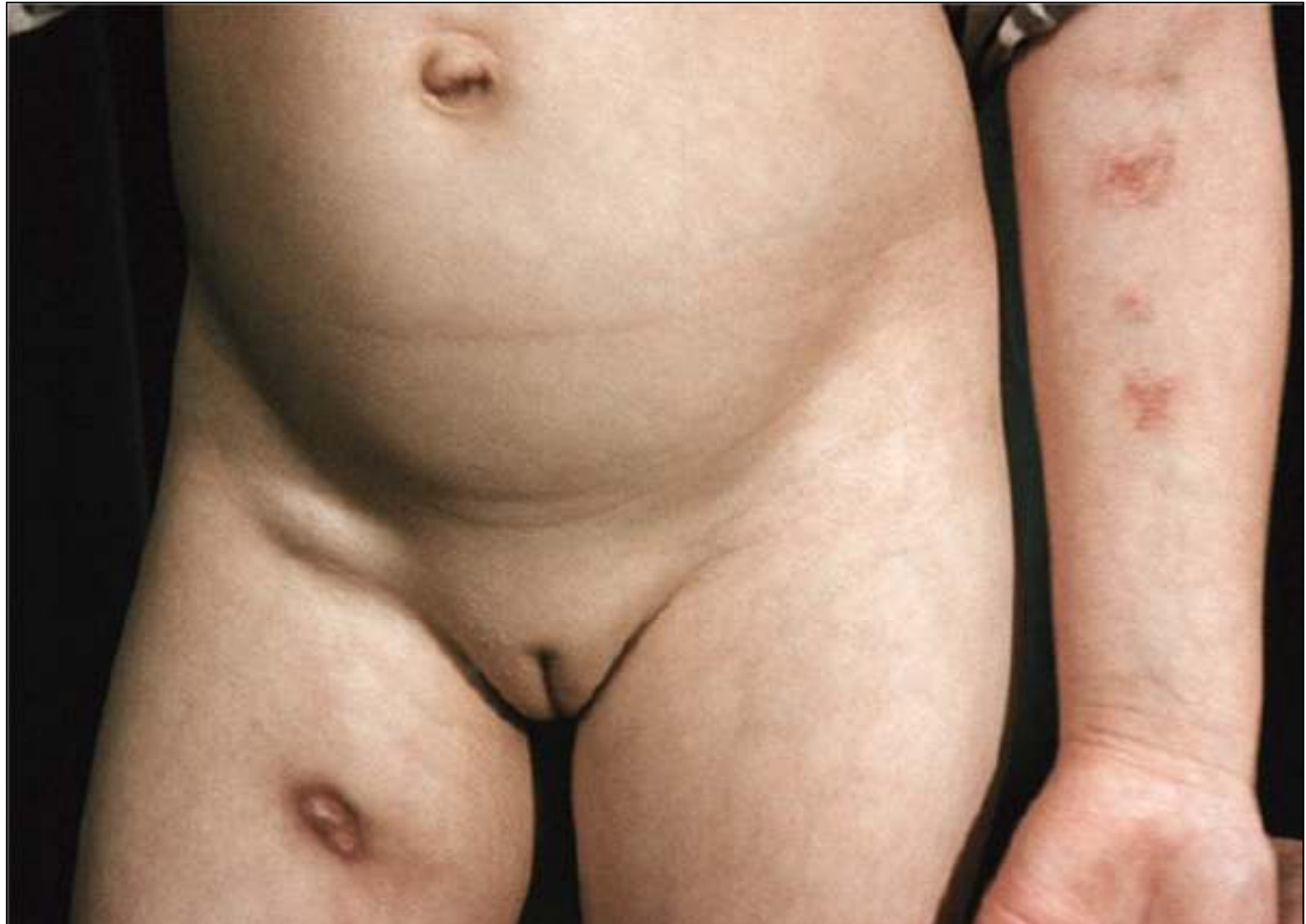

# Primary inoculation tuberculosis: clinical manifestations

- Initially, papule occurs at the inoculation site 2 to 4 weeks after the wound. Lesions enlarges to a painless ulcer, so called tuberculous chancre (up to 5 cm), with shallow granular base and multiple tiny abscesses or may be covered by thick crust.
- Undermined margins; deeper inoculation results in subcutaneous abscess
- Most common on exposed skin at sites of minor injuries
- Oral lesions occur after ingestion of bovine bacilli in non-pasteurized milk; intra-oral inoculation results in ulcers on gingiva or palate
- Regional lymphadenopathy occurs within 3 to 8 weeks.



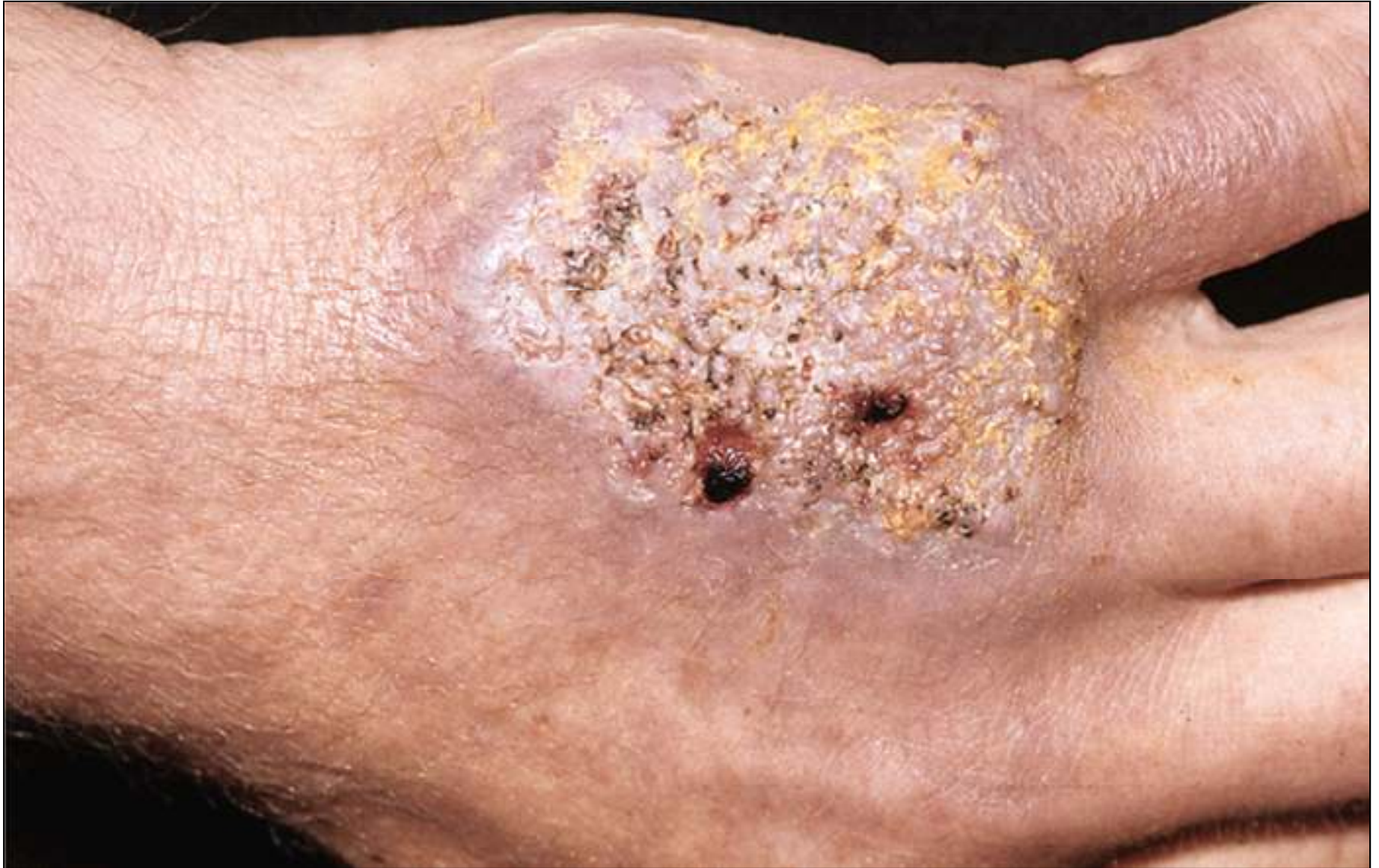# TBC chancre, or primary inoculation tuberculosis



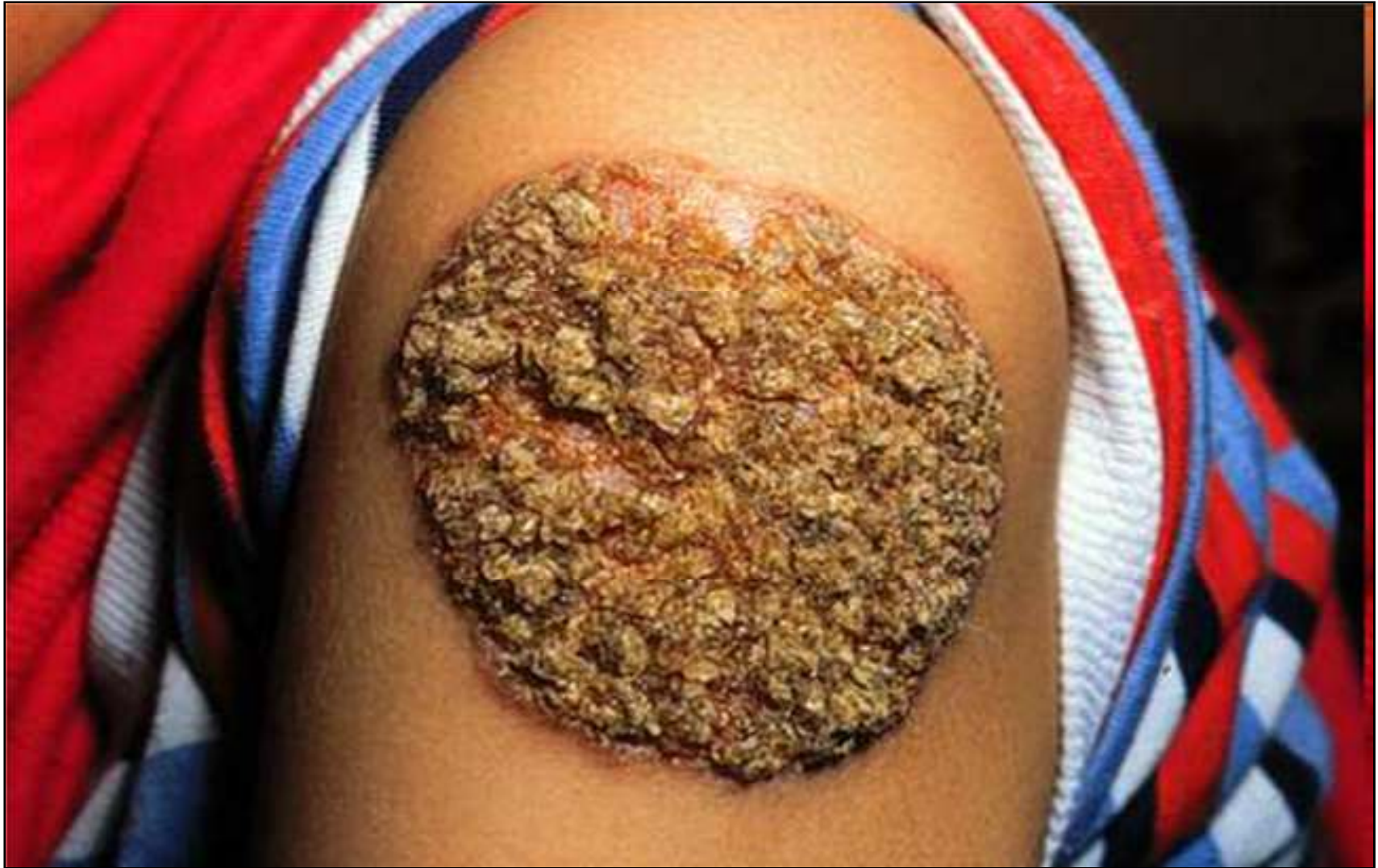# Tuberculosis verrucosa cutis: clinical manifestations

- Initial papule with violaceous halo
- Evolves to hyperkeratotic, warty, firm plaque
- Clefts and fissures occur from which pus and keratinous material can be expressed
- Border often irregular; lesions are usually single, most commonly on dorsolateral hands and fingers
- In children, lower extremities, knees
- No lymphadenopathy.

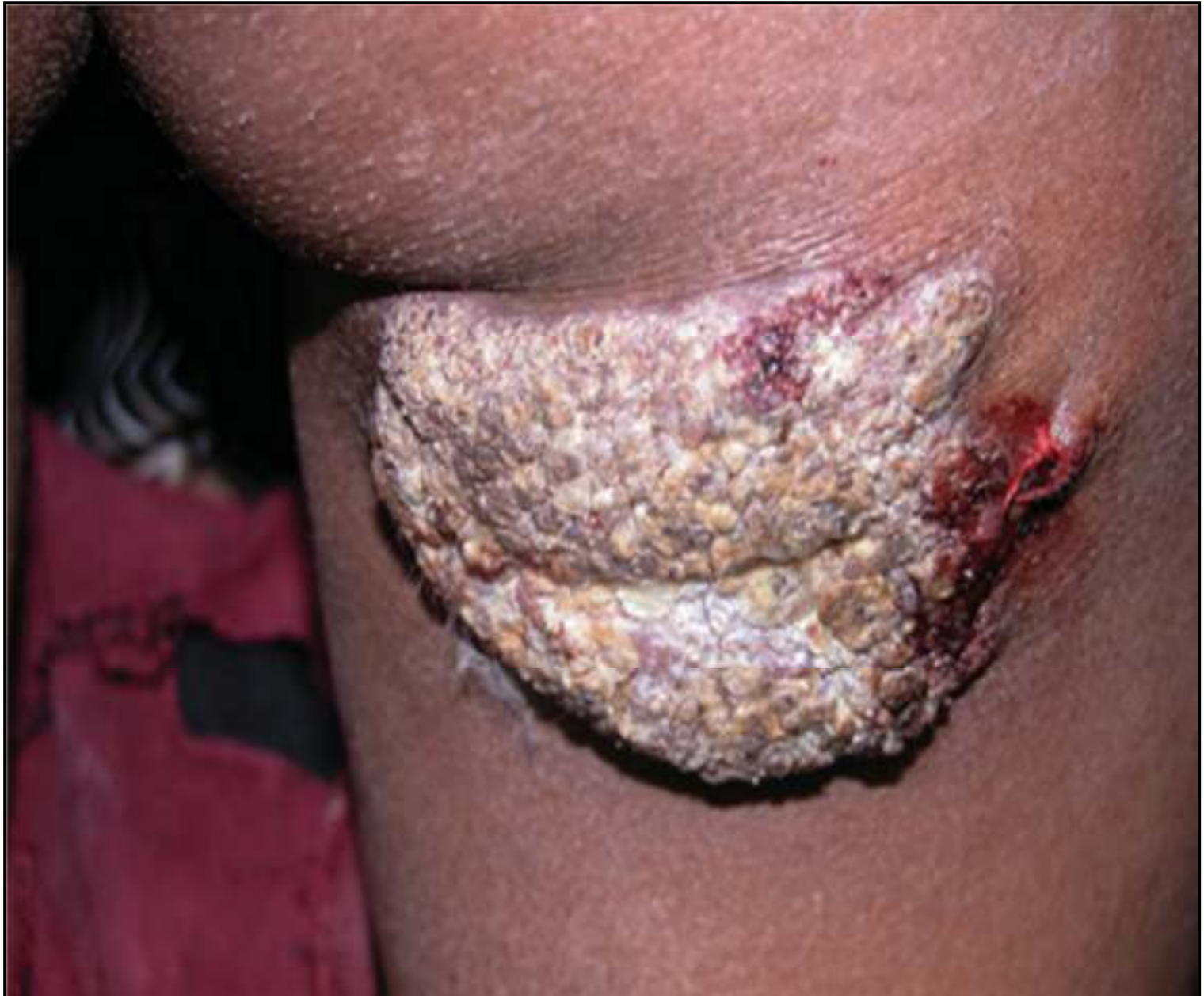# Tuberculosis verrucosa cutis



# Tuberculosis verrucosa cutis



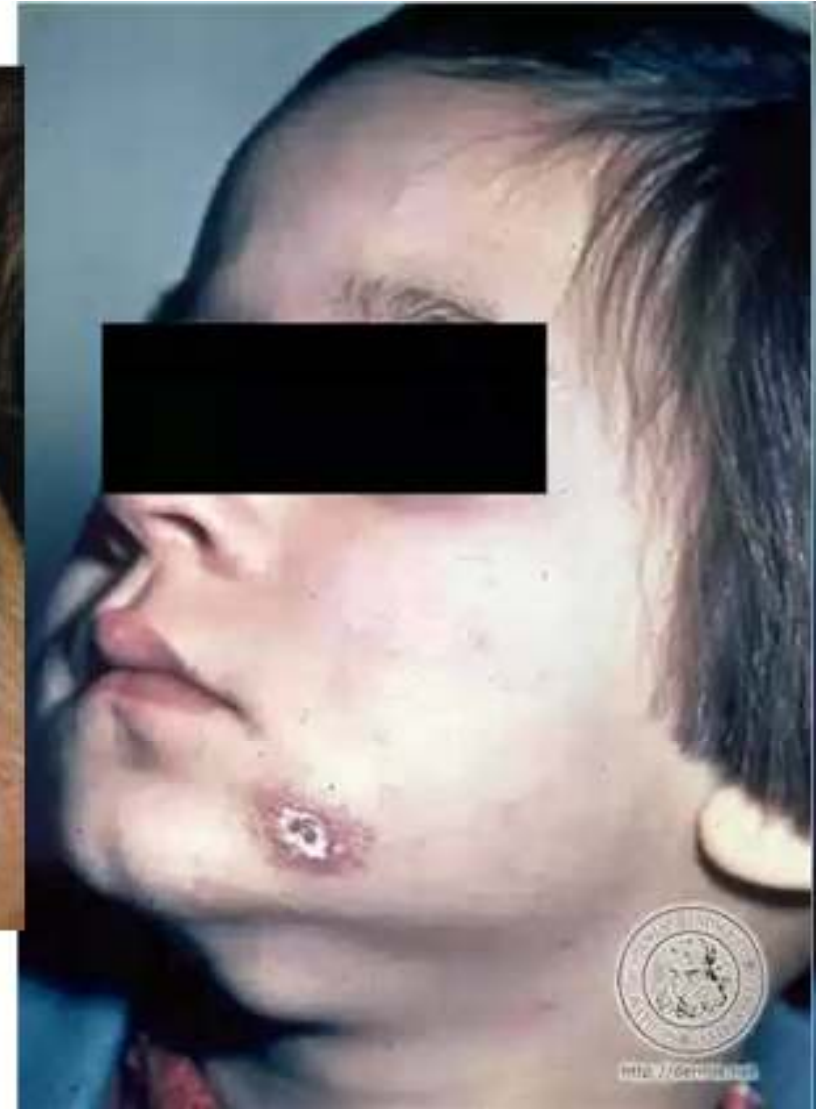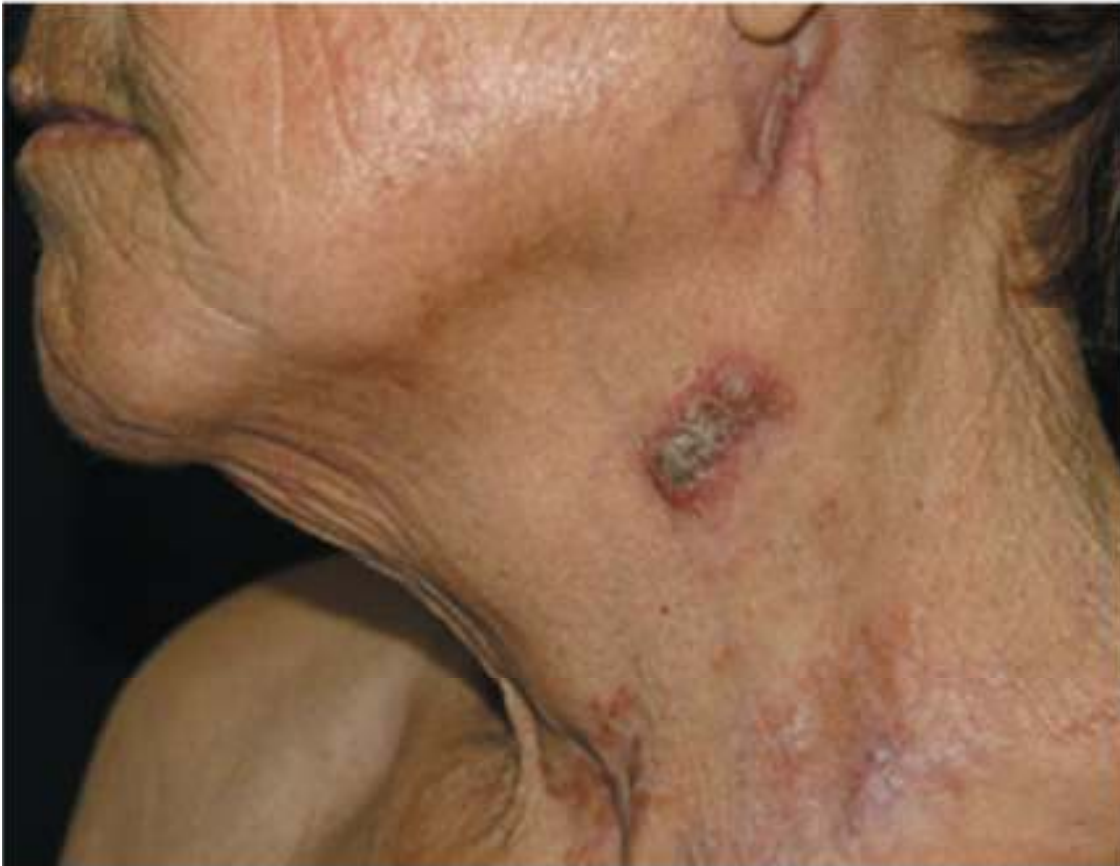# Tuberculosis verrucosa cutis



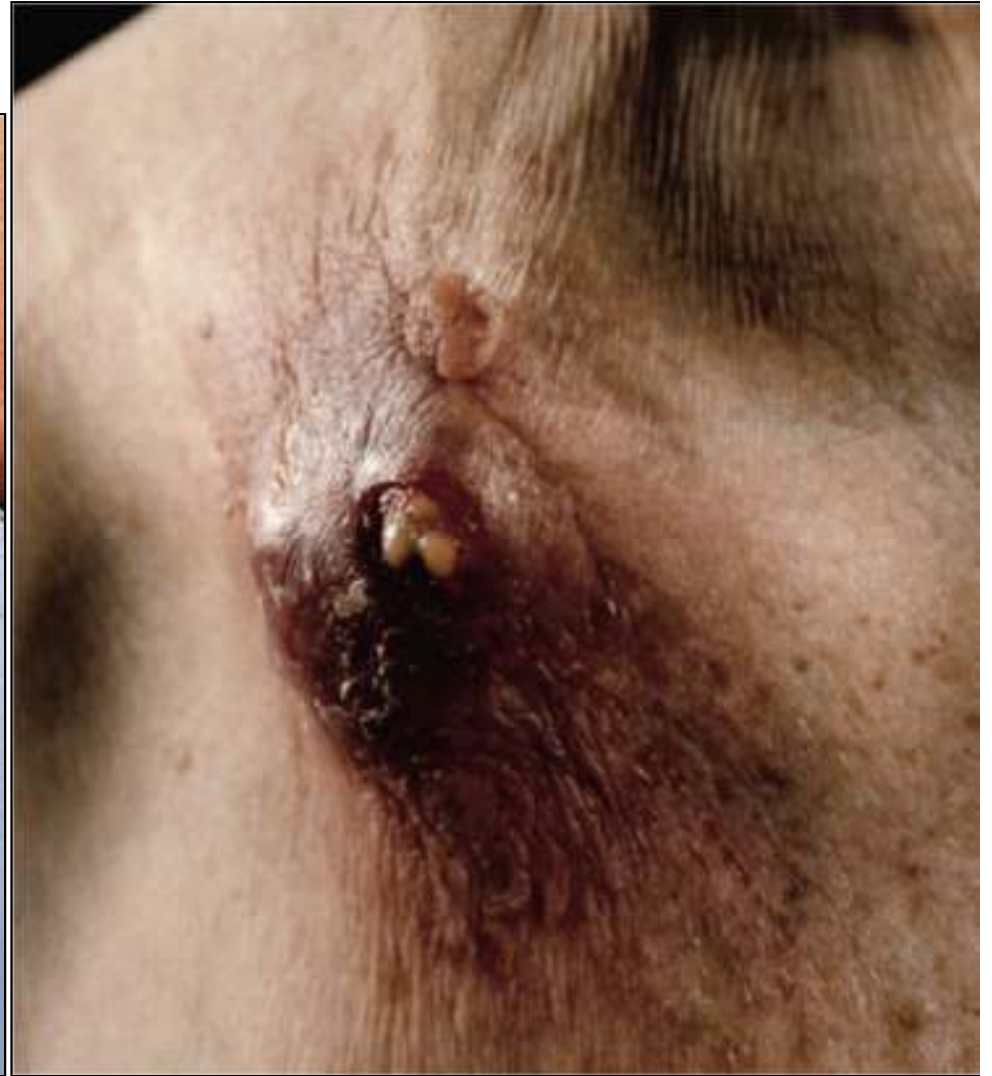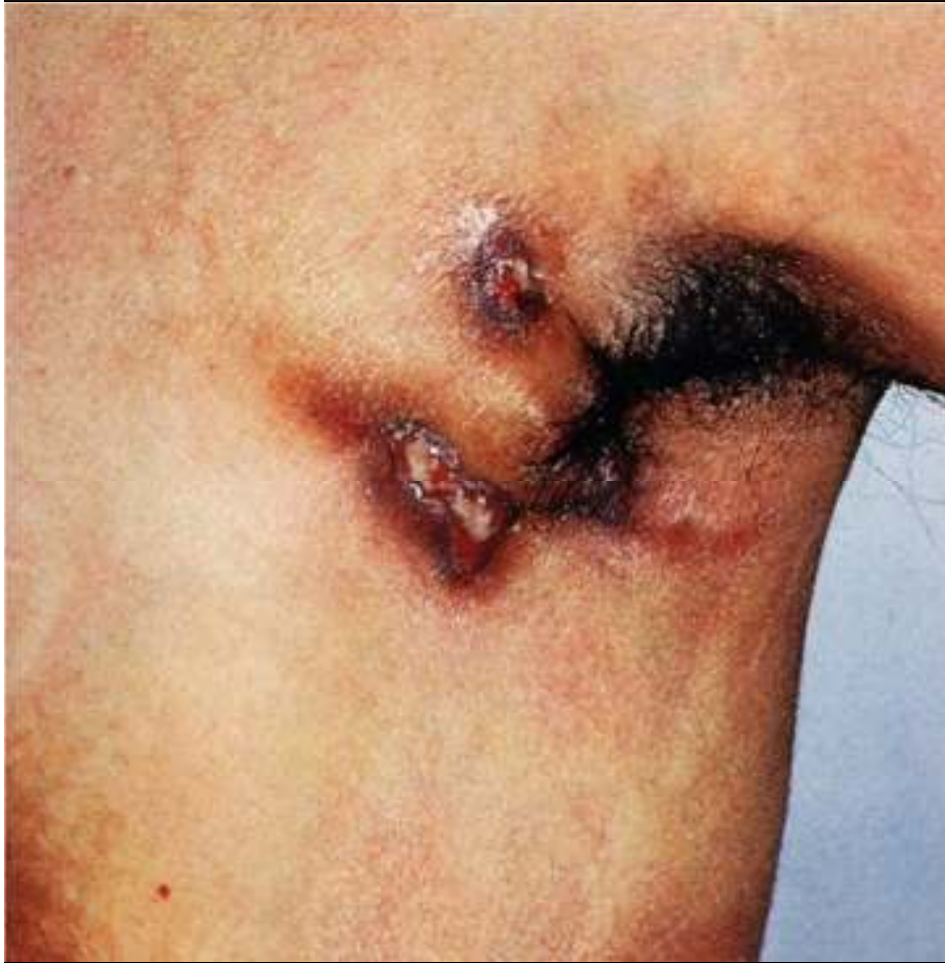# Scrofuloderma: clinical manifestations

- Firm subcutaneous nodule that initially is freely movable; the lesion then becomes doughy and evolves into an irregular, deep-seated node or plaque that liquefies and perforates.
- Ulcers and irregular sinuses, usually of linear or serpiginous shape, discharge pus or caseous material. Edges are undermined, inverted, and dissecting subcutaneous pockets alternating with soft, fluctuating infiltrates and bridging scars.
- Most often occurs in the parotidal, submandibular, and supraclavicular regions; lateral neck.
- Scrofuloderma most often results from continuous spread from affected lymph nodes or tuberculous bones (phalanges, sternum, ribs) or joints.

# Scrofuloderma



# SCROFULODERMA

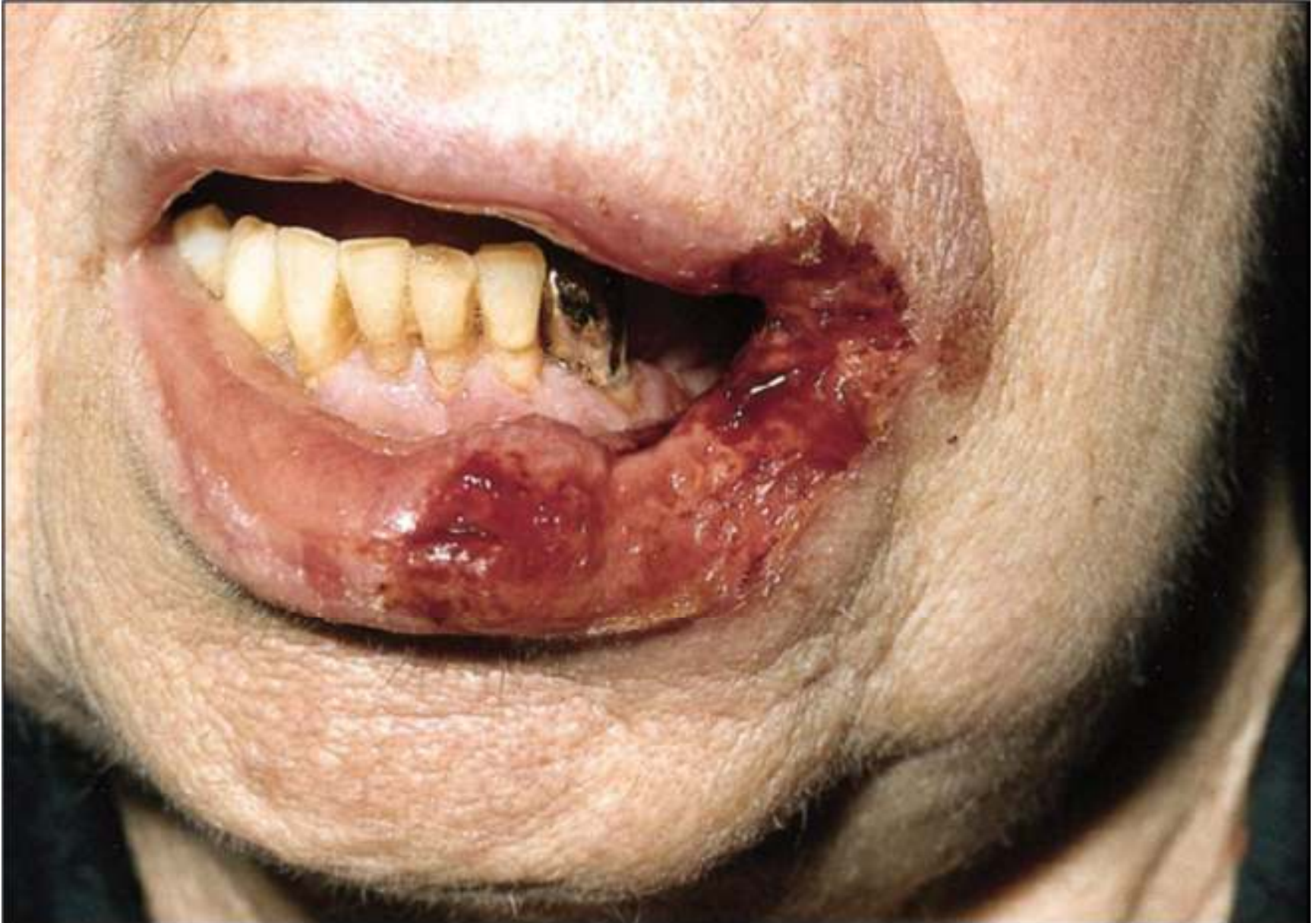



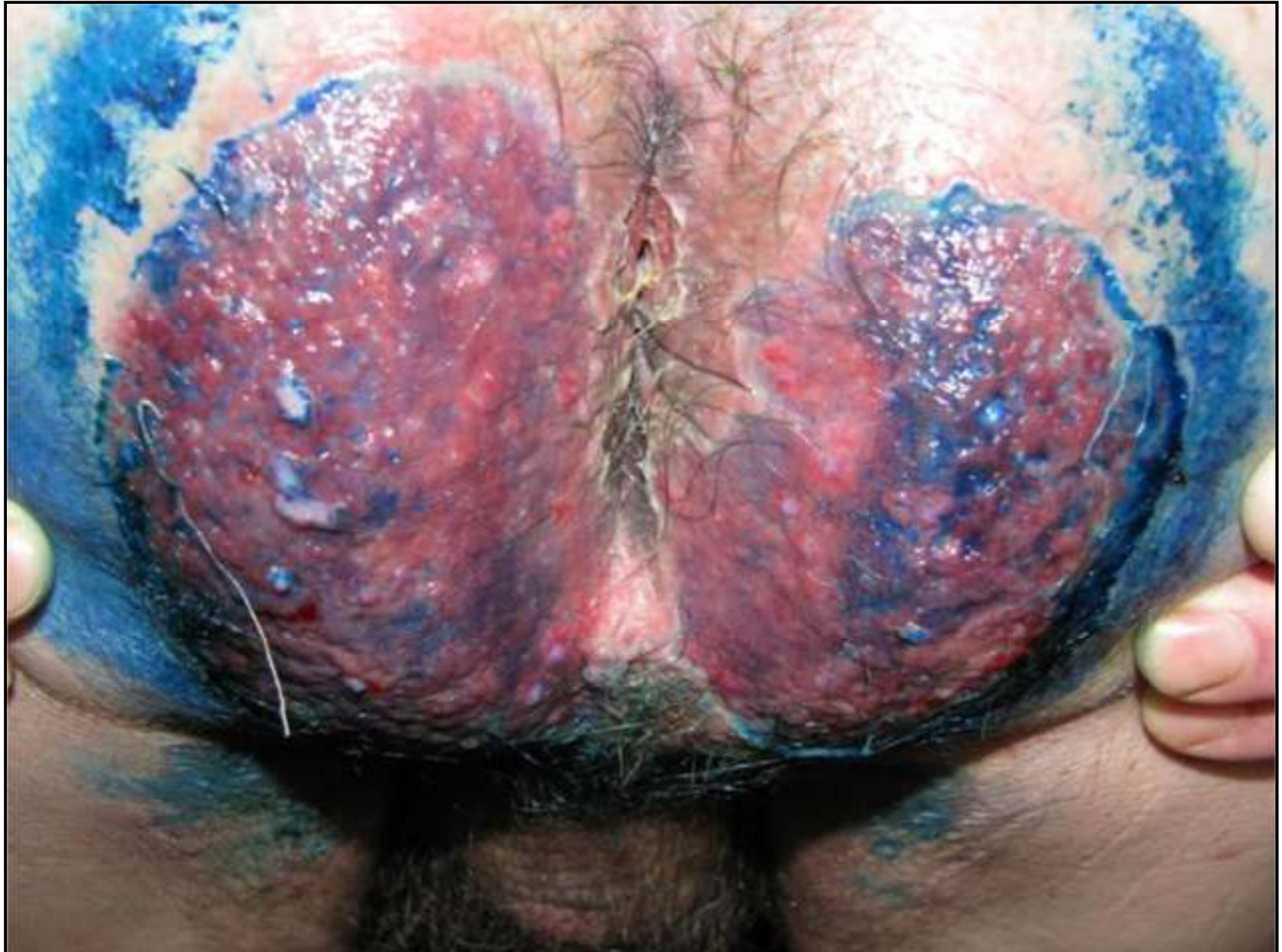# Orificial tuberculosis: clinical manifestations

- Small yellowish nodule on mucosa breaks down to form painful circular or irregular ulcer with undermined borders and pseudomembranous material, yellowish tubercles, and eroded vessels at its base.
- Surrounding mucosa is swollen, edematous, and inflamed.
- Since orificial tuberculosis results from autoinoculation of mycobacteria from progressive tuberculosis of internal organs, it is usually found on the oral, pharyngeal (pulmonary tuberculosis), vulvar (genitourinary tuberculosis), and anal (intestinal tuberculosis) mucous membranes.
- Lesions may be single or multiple, and in the mouth most often occur on the tongue, soft and hard palate, or lips.

# Orificial tuberculosis



# Orificial tuberculosis: Trelat granulations

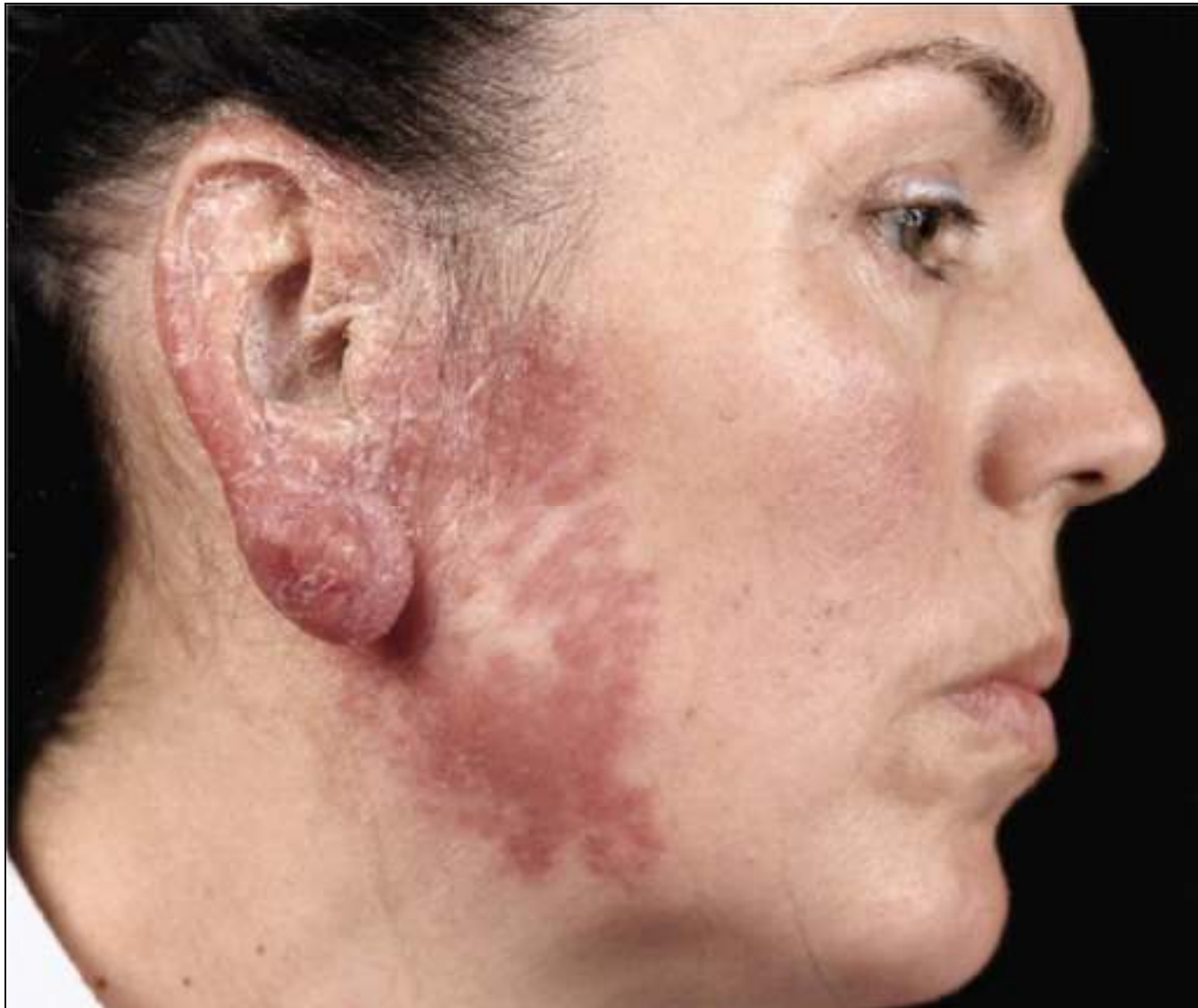

# Lupus vulgaris: clinical manifestations

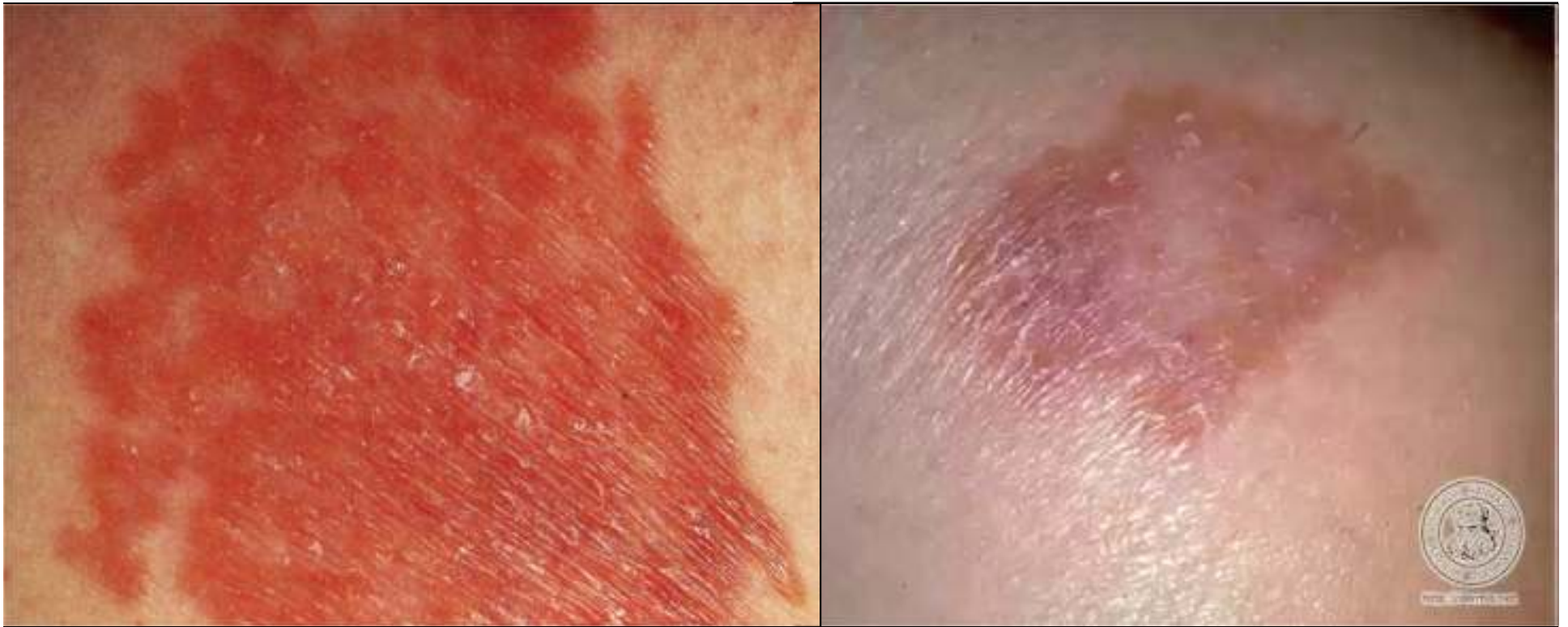- Initial flat papule is ill-defined, irregular plaque
- Reddish-brown: diascopy (the use of a glass slide pressed against the skin) reveals an “apple jelly” (yellowish-brown color)
- The consistency is characteristically soft; if the lesion is probed, the instrument breaks through the overlying epidermis
- Surface is initially smooth or slightly scaly but may become hyperkeratotic
- Hypertrophic forms result in soft tumorous nodules
- Ulcerative forms present as punched-out, often serpiginous ulcers surrounded by soft, brownish infiltrate
- Usually solitary, but several sites may occur
- Most lesions on the head and neck, most often on nose and ears or scalp
- Involvement of underlying cartilage but not bone results in its destruction (ears, nose)
- Scarring is prominent and characteristically new brownish infiltrates occur within atrophic scars.

# TBC LUPUS

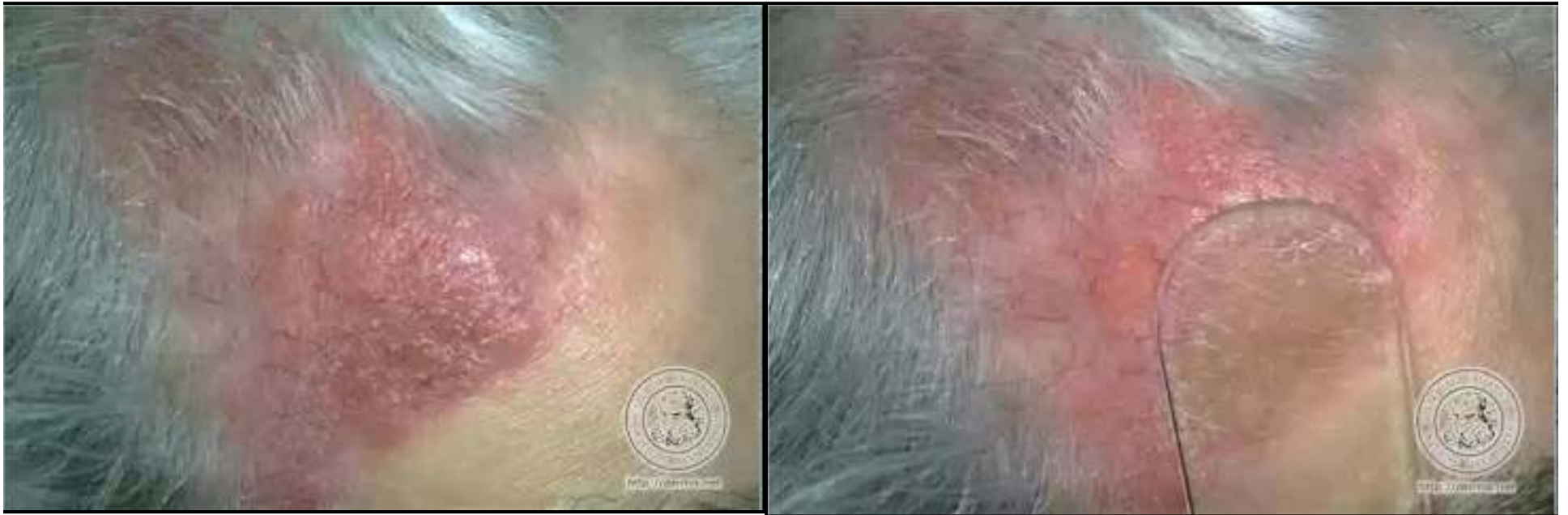(lupus vulgaris or Willan lupus)



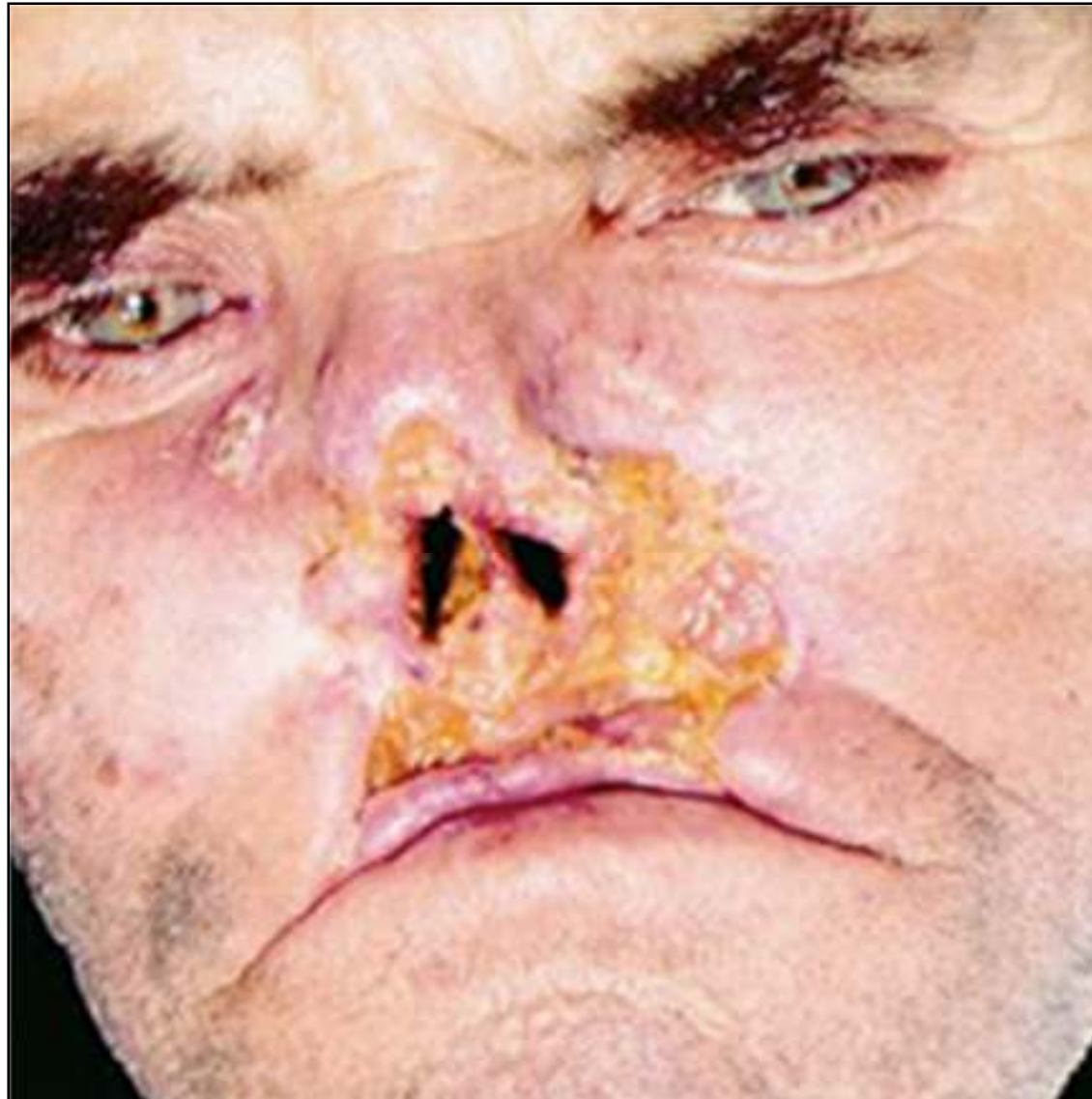# TBC LUPUS: lupoma (tubercle/nodule)



# TBC lupus: apple jelly sign

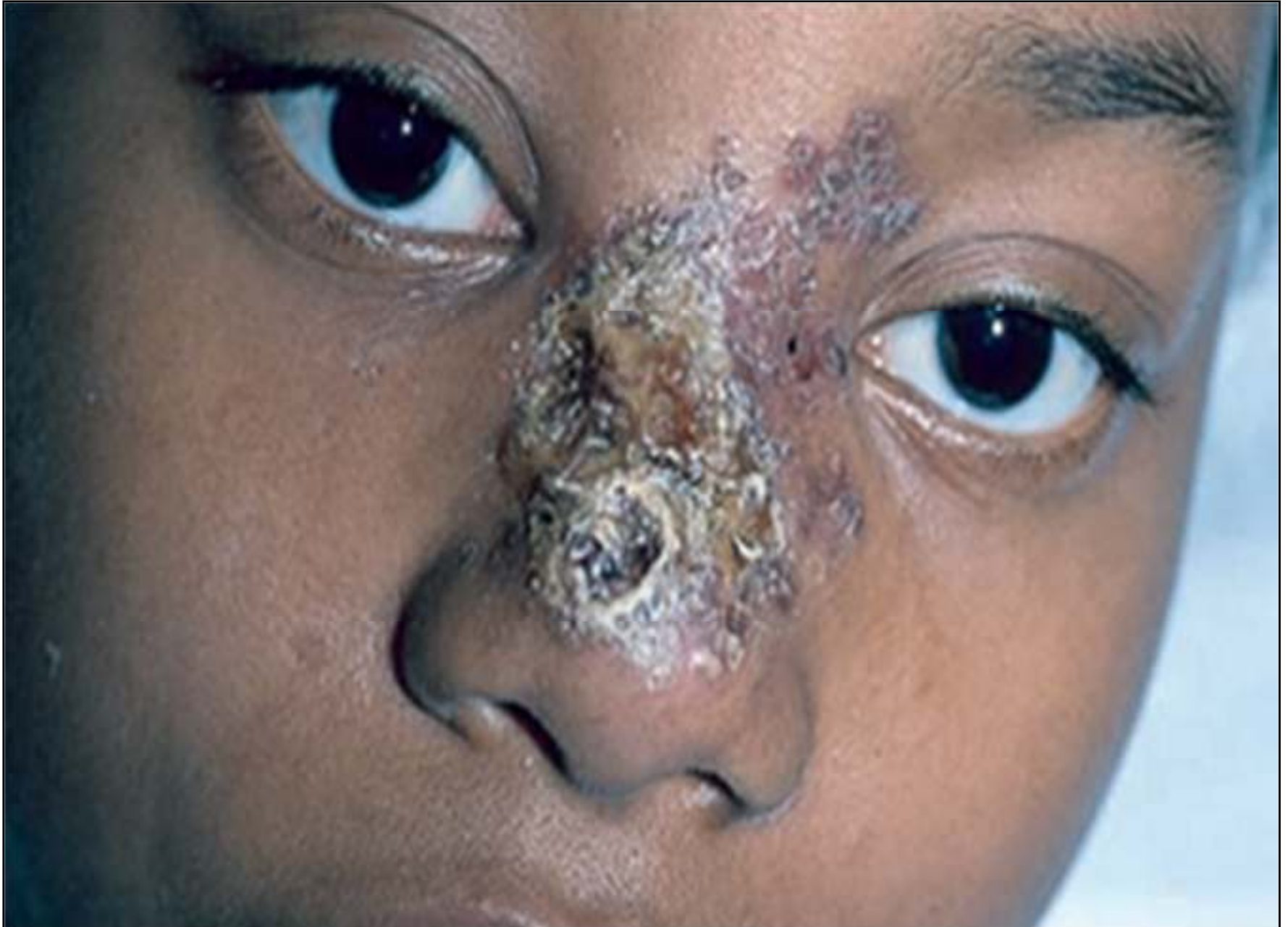

# TBC lupus: mutilations

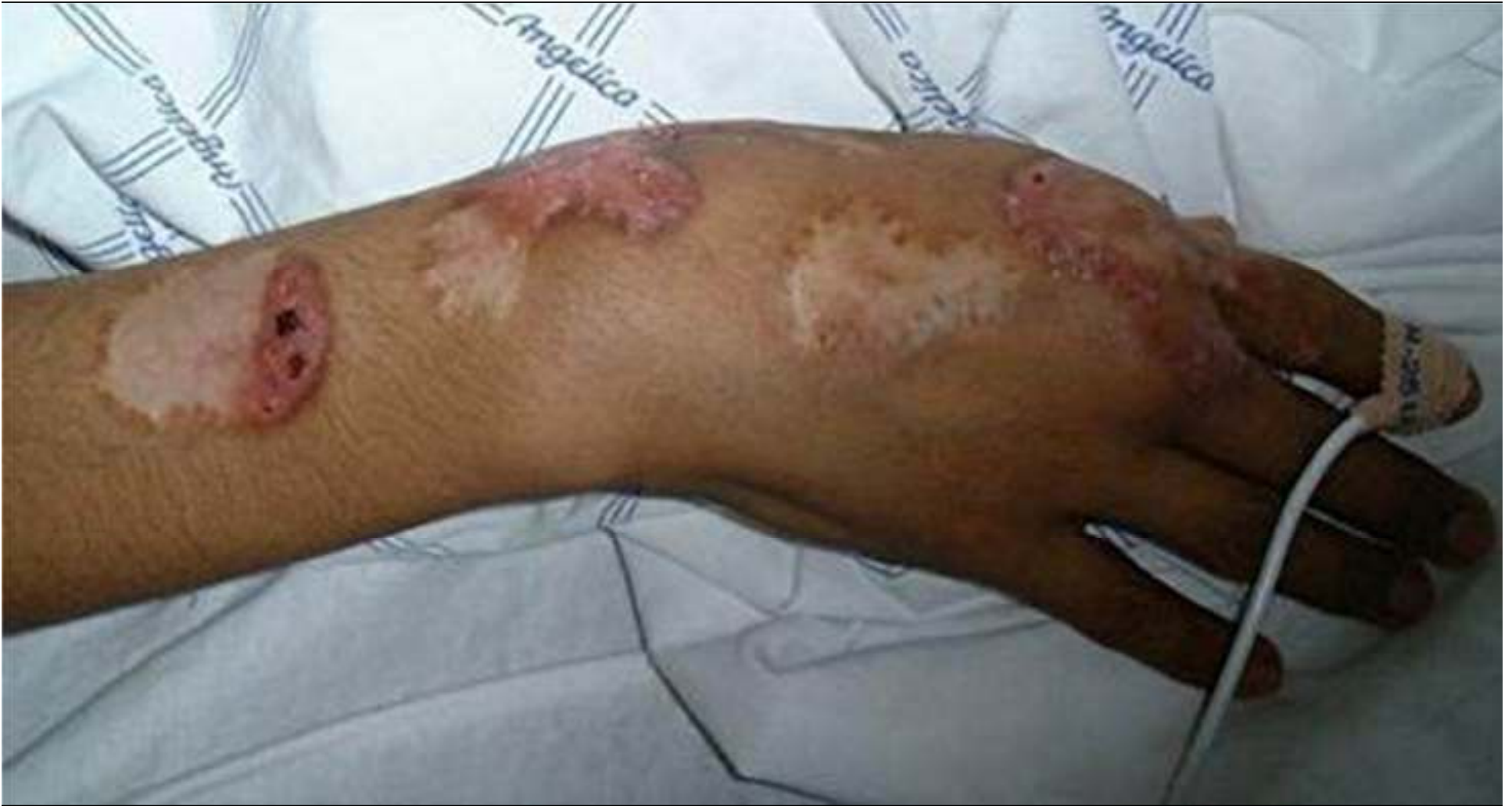



# TBC lupus: mutilations



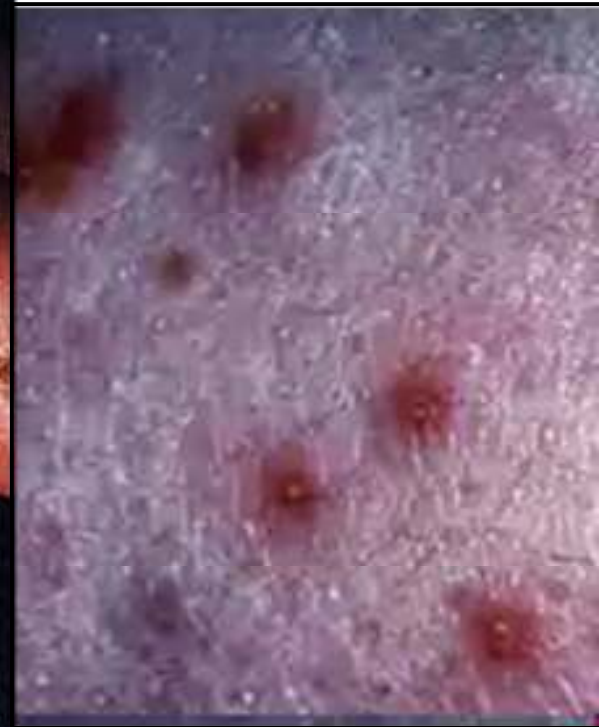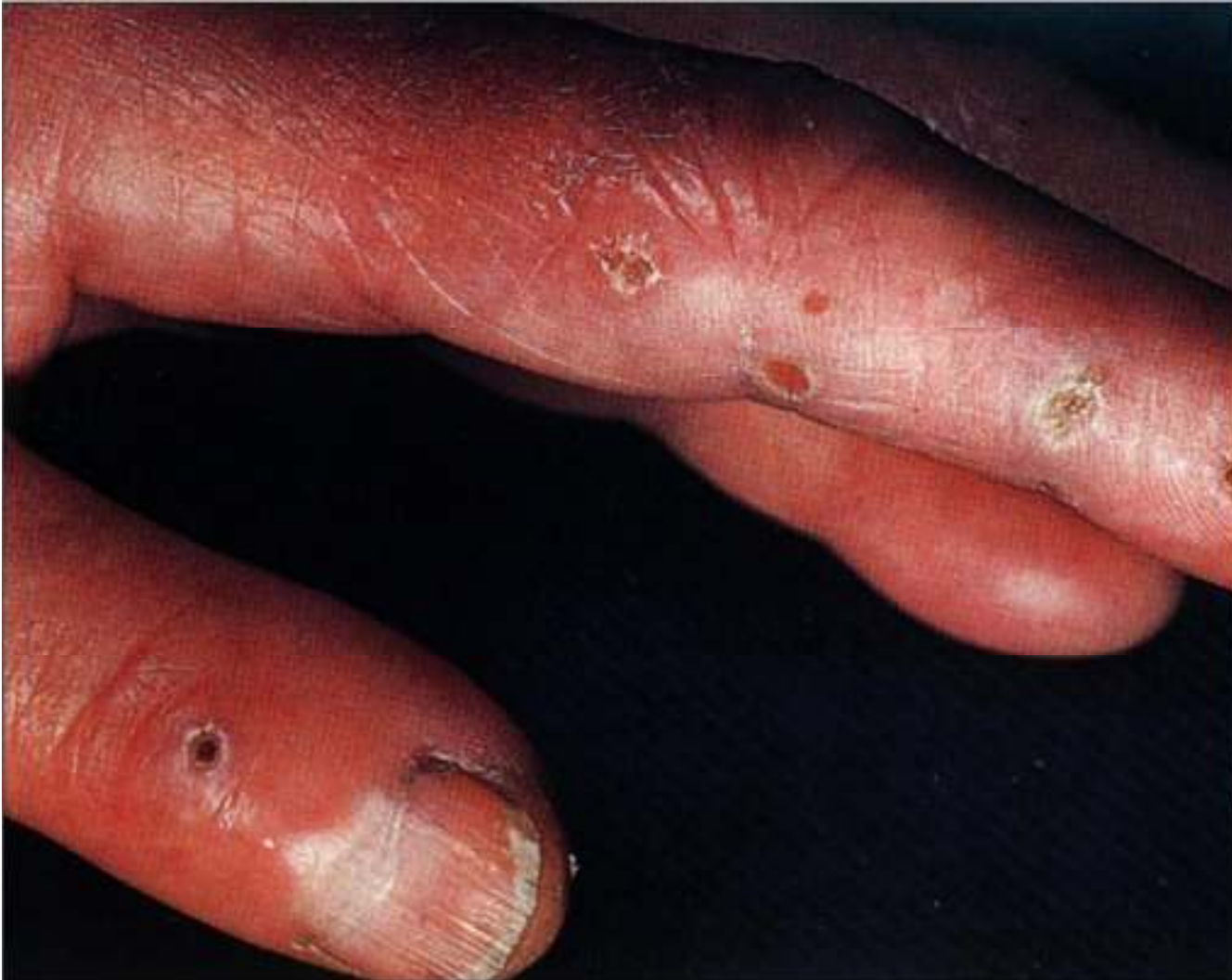# TBC lupus: cicatricial atrophy



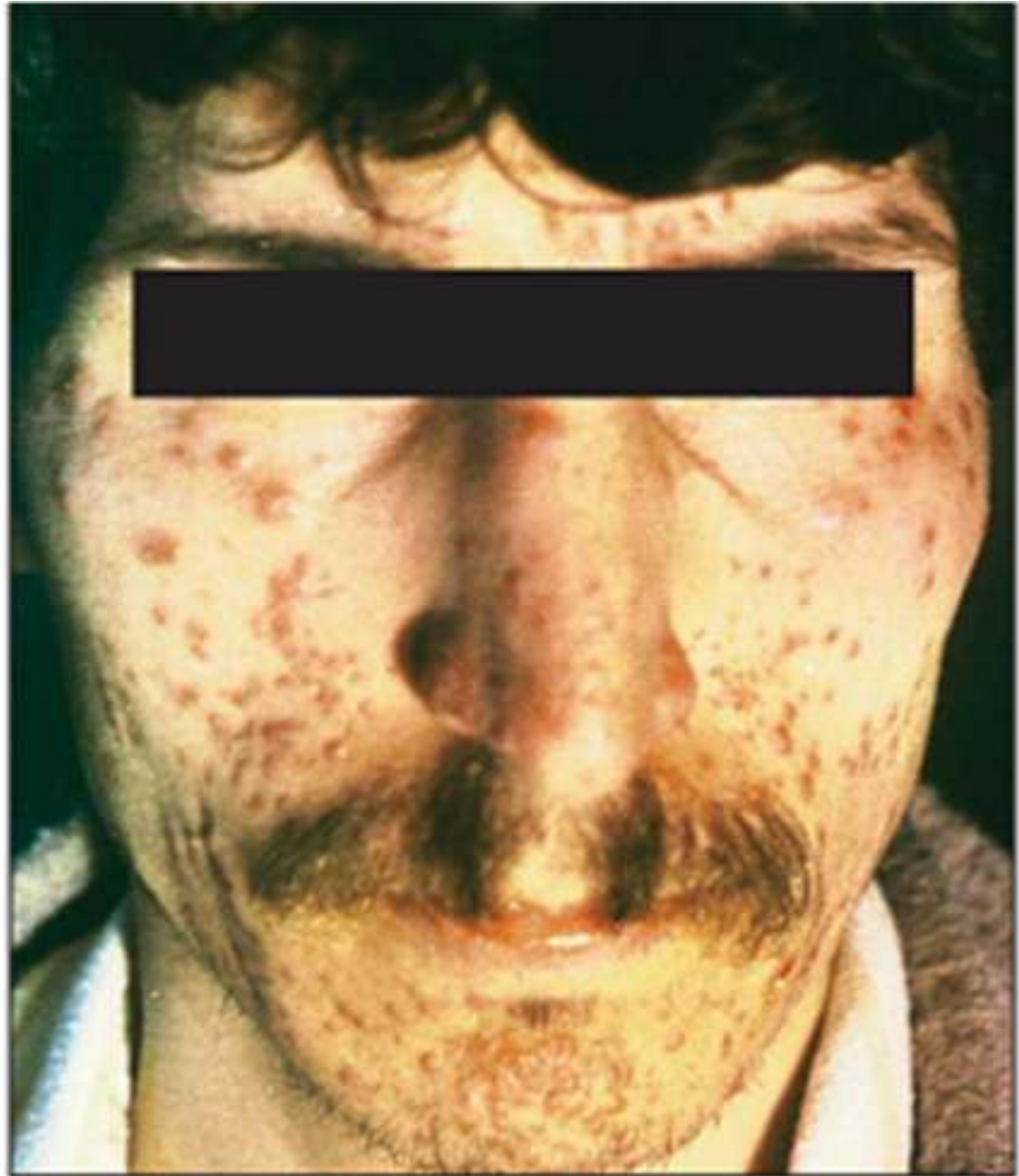## Acute miliary tuberculosis: clinical manifestations

- Exanthem: disseminated lesions are minute macules and papules or purpuric lesions; sometimes are vesicular and crusted.
- Removal of crust reveals umbilication.
- Disseminated on all parts of the body, particularly the trunk.

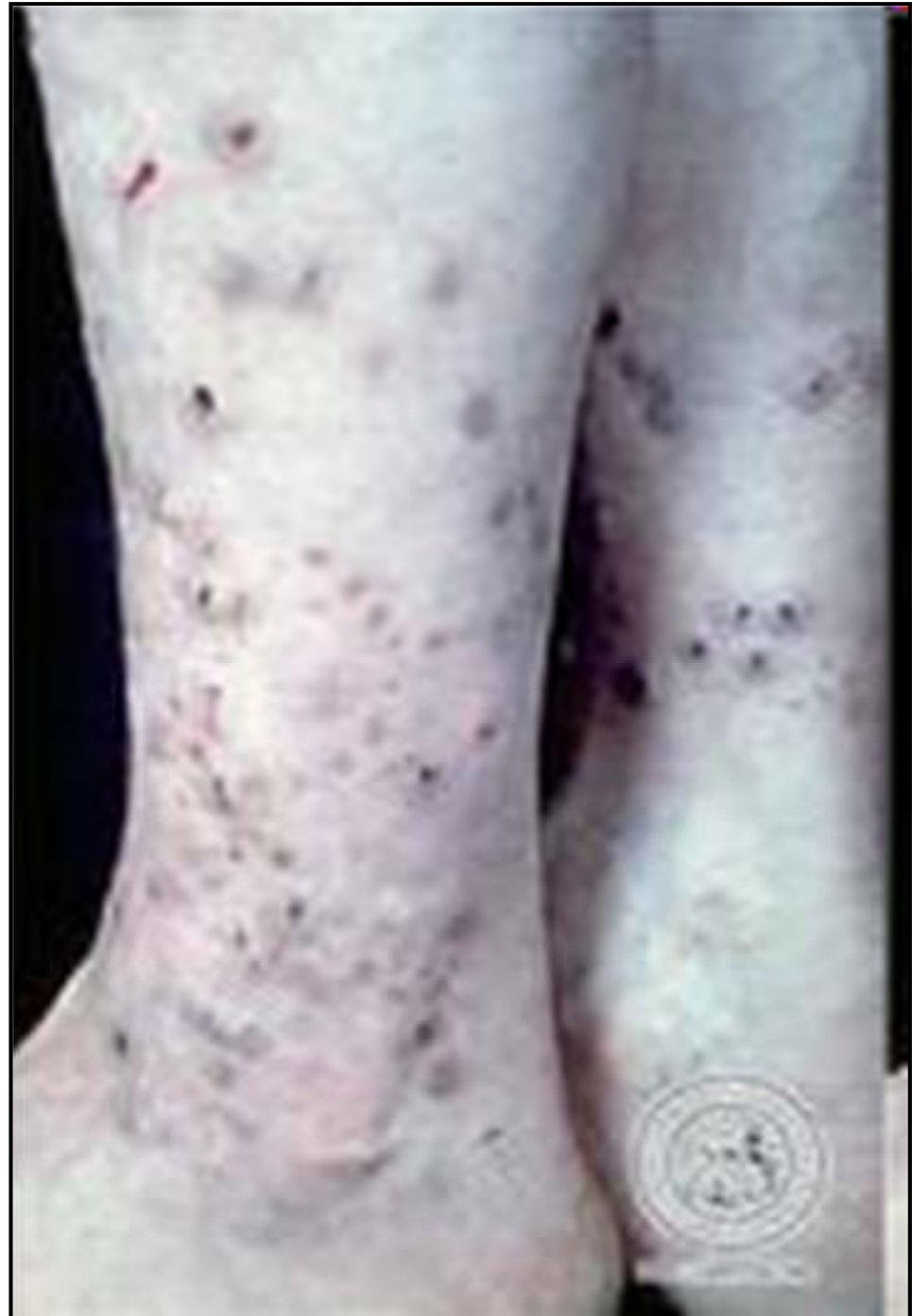# TUBERCULIDES: PAPULO-NECROTIC TBC



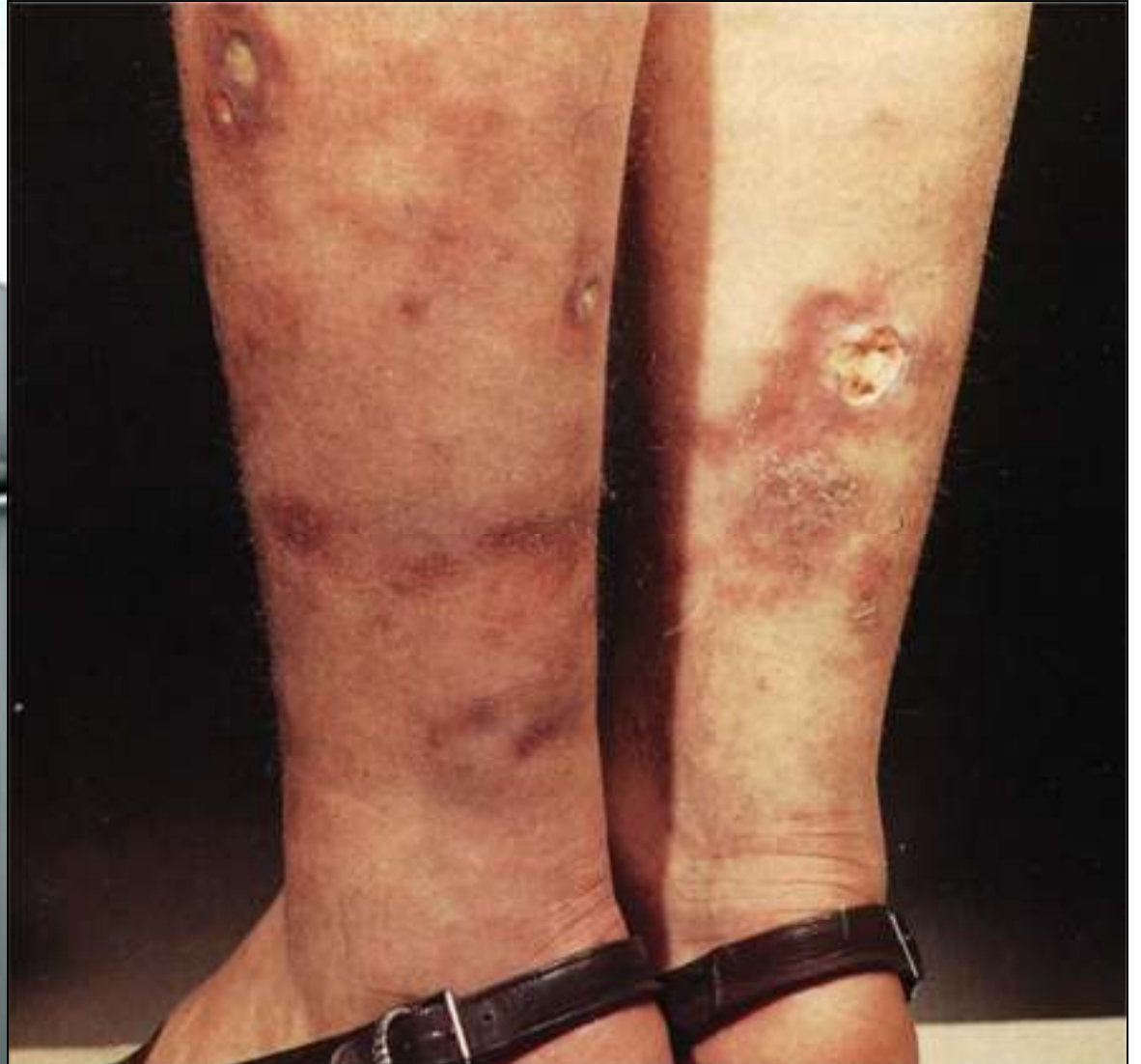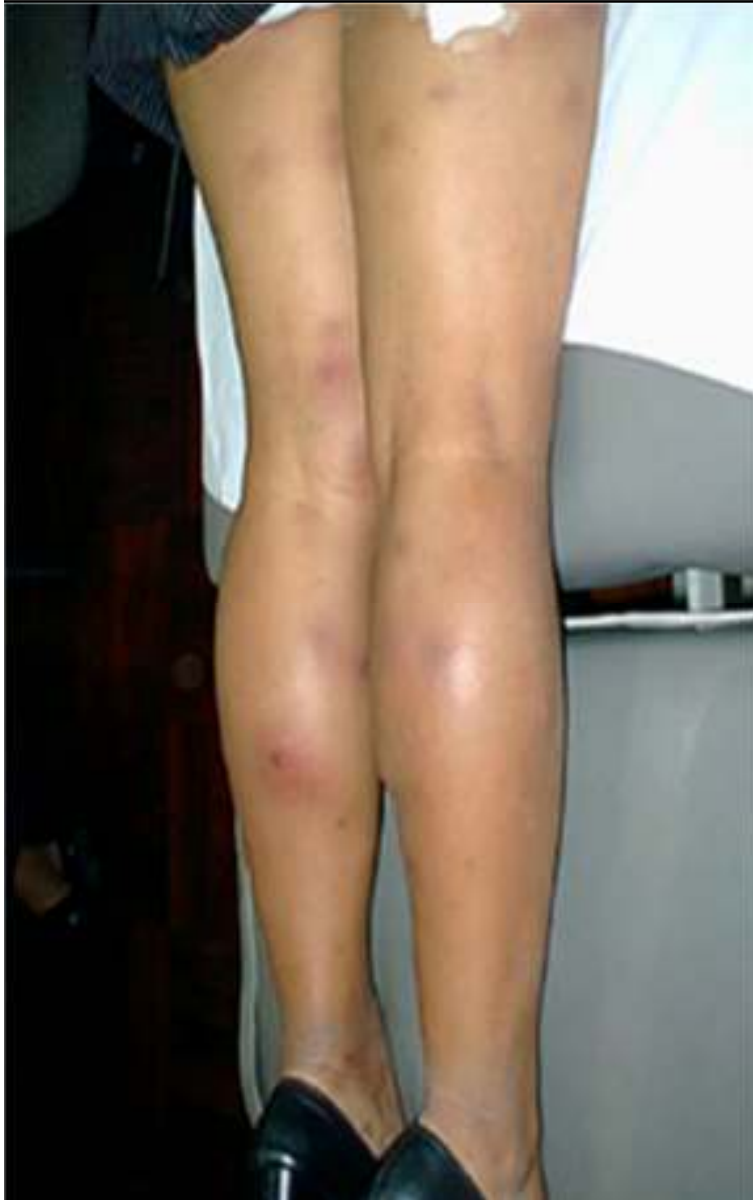Tuberculides:  
acnitis type



Tuberculides:  
folliclis type



# TUBERCULIDES: INDURATIVE ERYTHEMA OF BAZIN

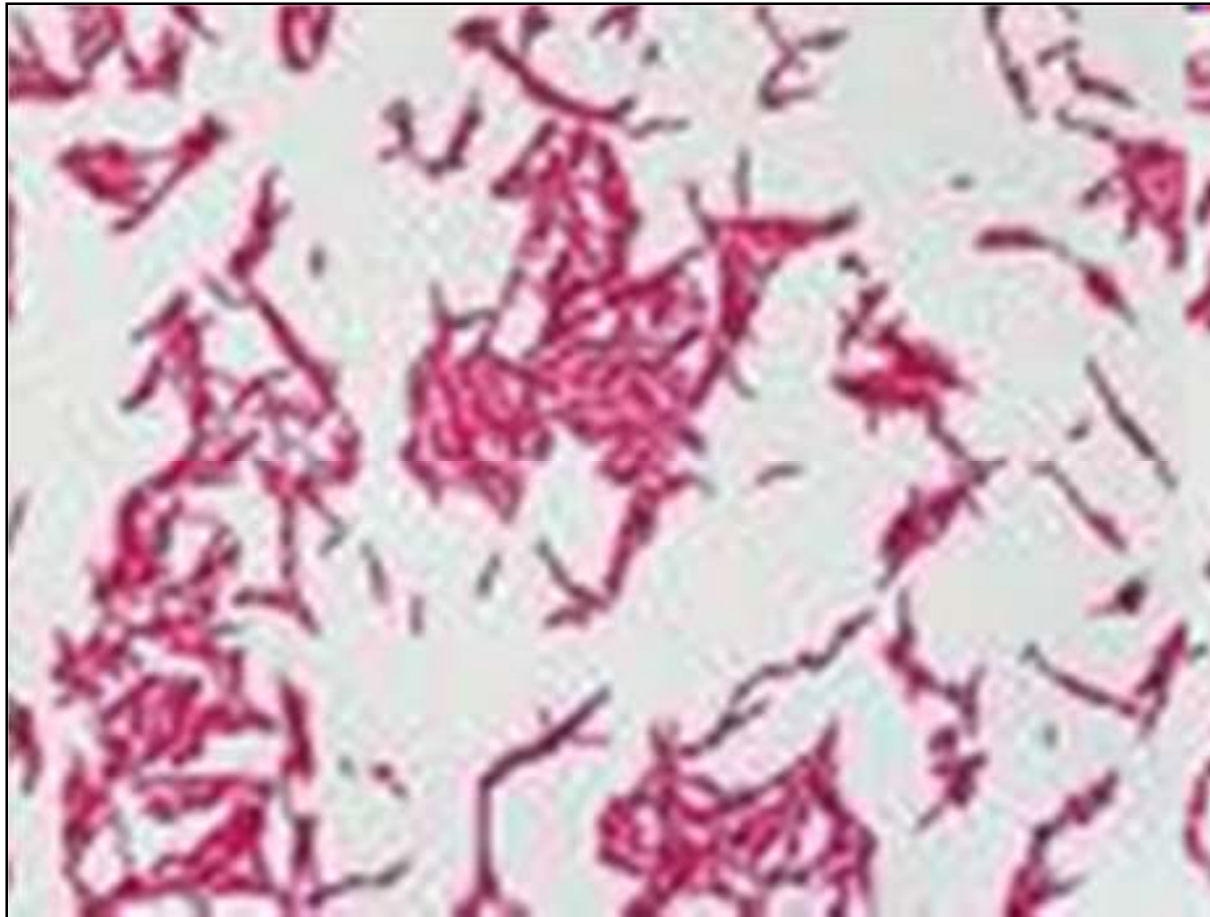


# Laboratory examinations

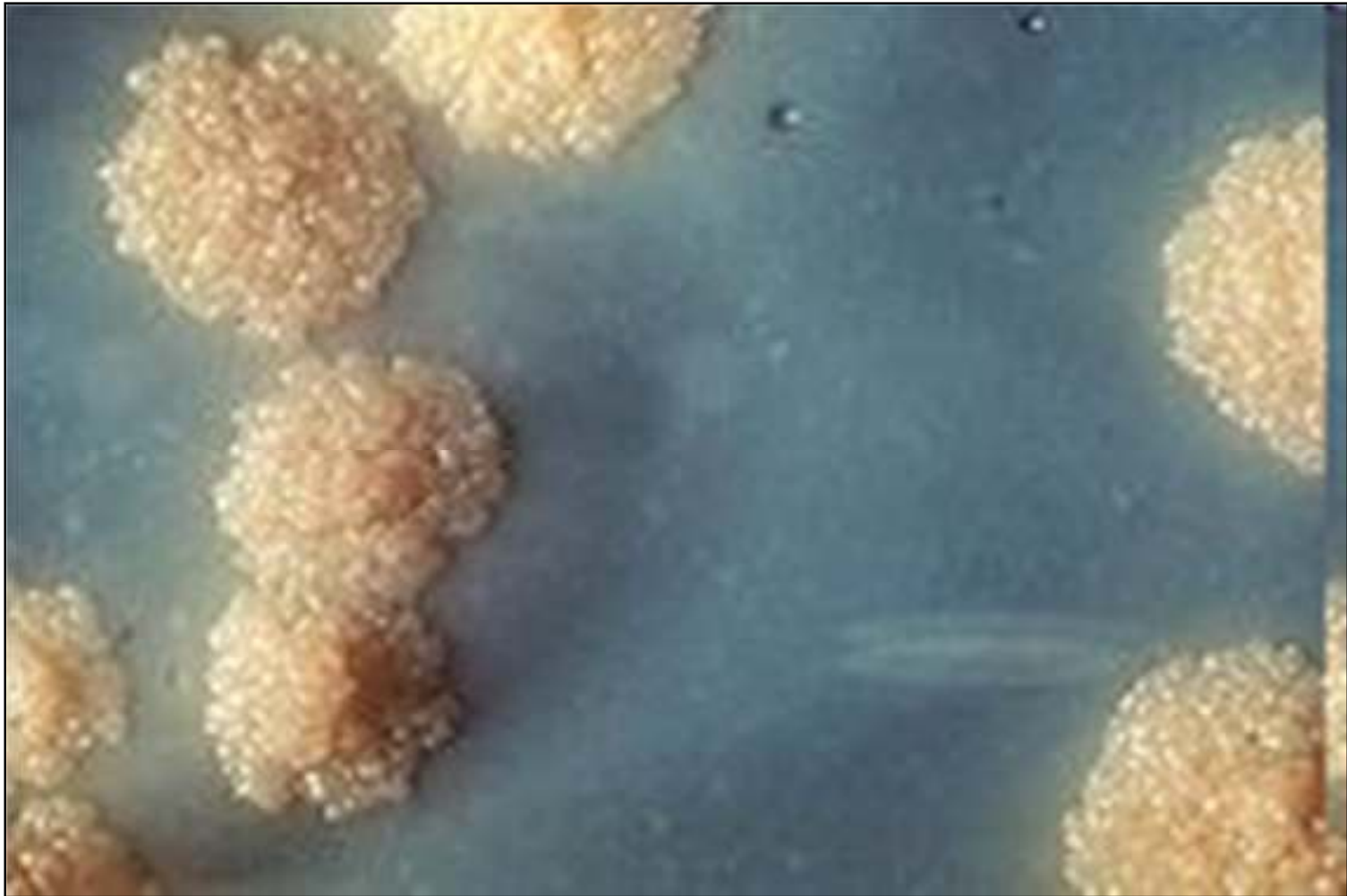- Dermatopathology and microscopy: epithelioid cells, Langhans giant cells, lymphocytes, caseation necrosis – tubercle pattern
- Culture: possible in case of lupus vulgaris or warty tuberculosis
- PCR: standard procedure to identify *M.tuberculosis* DNA in tissue specimens.
- PPD: tuberculin Purified Protein Derivative is an intracutaneous skin test (idr). Skin testing consists of intradermal injection into the volar surface of the forearm (Mantoux method).



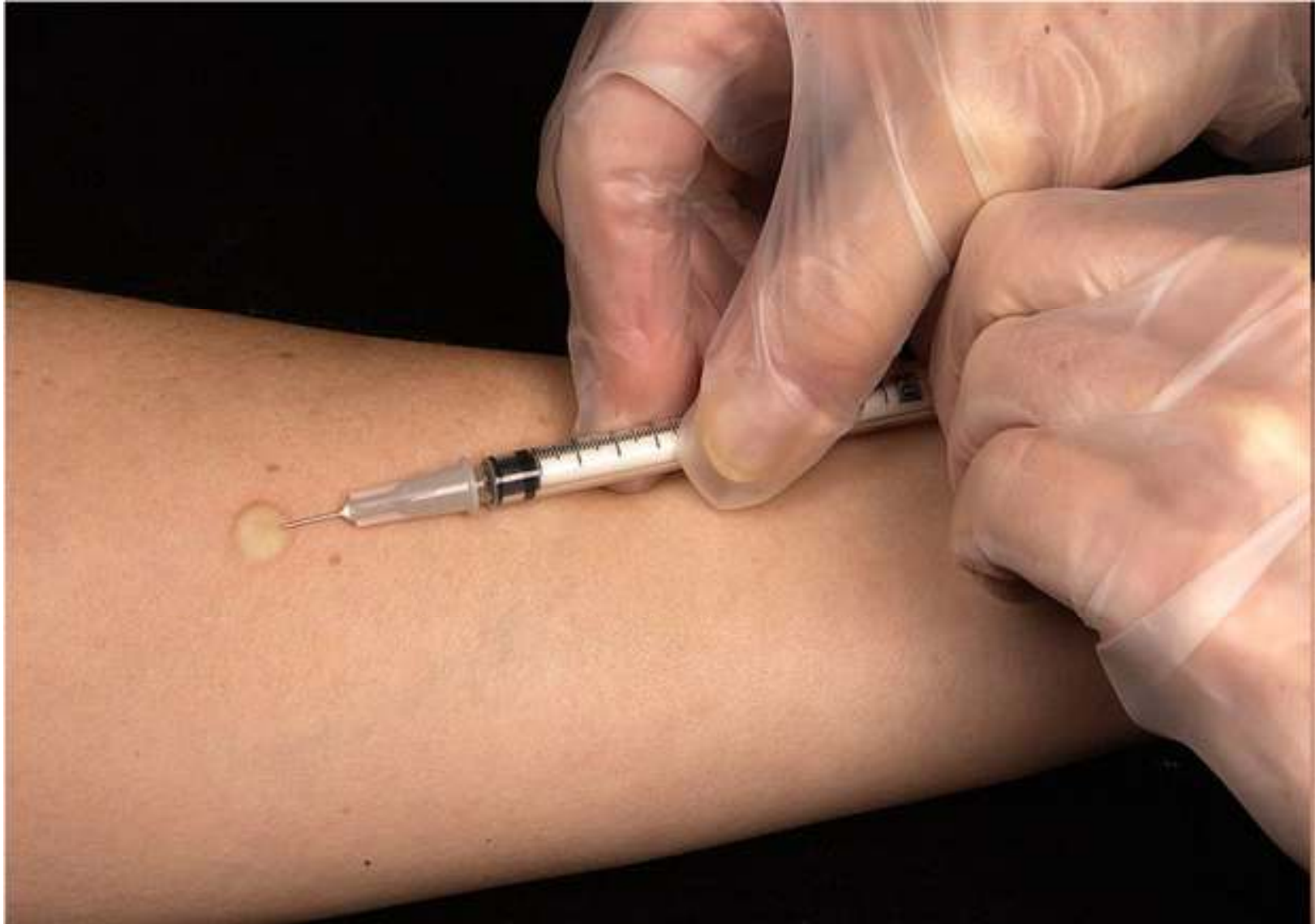# Microscopy: Ziehl-Nielsen staining



Culture: Löwenstein-Jensen (2-4 weeks);  
Agar-Middlebrook



# Testul cutanat la tuberculină (testul Mantoux)



## Виды реакций на пробу Манту

**Отрицательная реакция**  
(папула 0–1 мм)



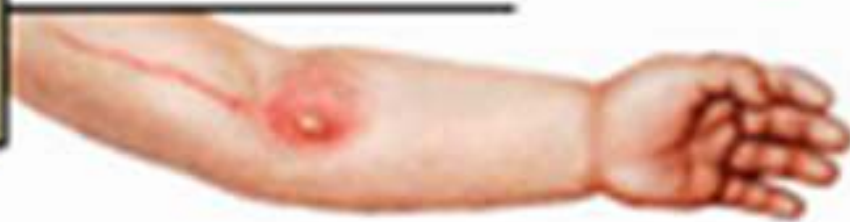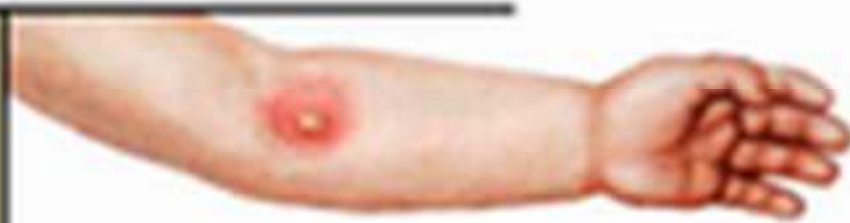**Сомнительная реакция**  
(папула 2–4 мм  
или гиперемия любого размера)

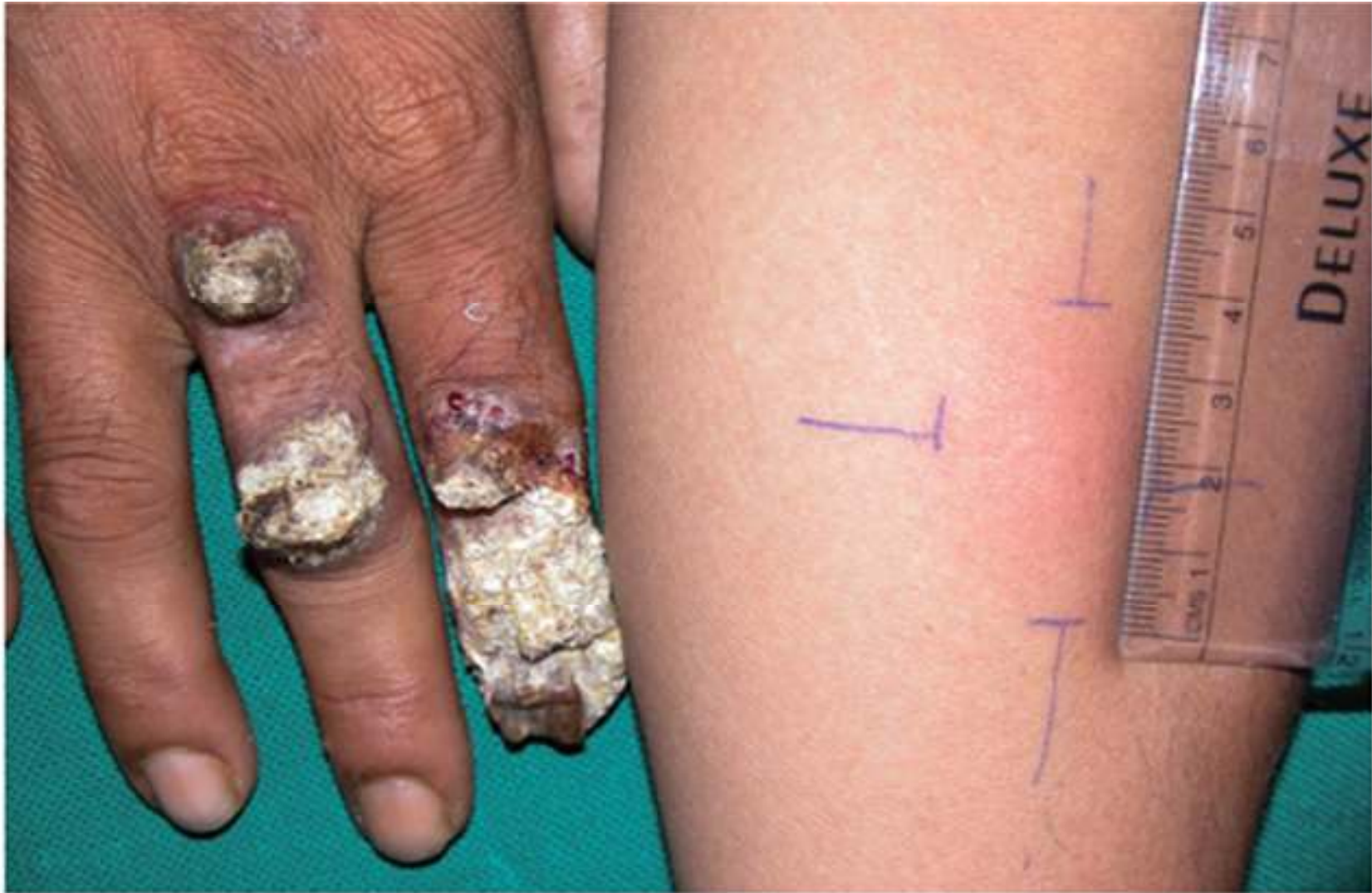

**Положительная реакция**  
(папула 5 мм и более)



**Гиперергическая реакция**  
(папула 16 мм и более  
или папула любого размера  
+ везикуло-некротическая  
реакция)





- 80-96,5% positivity in tuberculinic IDR

# Treatment

- First-line essential antituberculous drugs: isoniazid, rifampin, and rifabutin.
- First-line supplemental antituberculous drugs: pyrazinamide, ethambutol and streptomycine.
- Second line antituberculous drugs.
- 6 months protocol: an intensive 2 months therapy with four agents followed by 4 months therapy with isoniazid and rifampin.

# Leprosy (Hansen's disease)

- Definition: is a chronic granulomatous disease caused by *Mycobacterium leprae* and principally acquired during childhood or young adulthood.
- The skin, mucous membranes of the upper respiratory tract, and peripheral nerves are the major sites involvement in all form of leprosy.
- The clinical manifestations, natural history, and prognosis of leprosy are related to the host response; and the various types of leprosy represent the spectra of the host's immunologic response (cell-mediated immunity).

# DATE ISTORICE

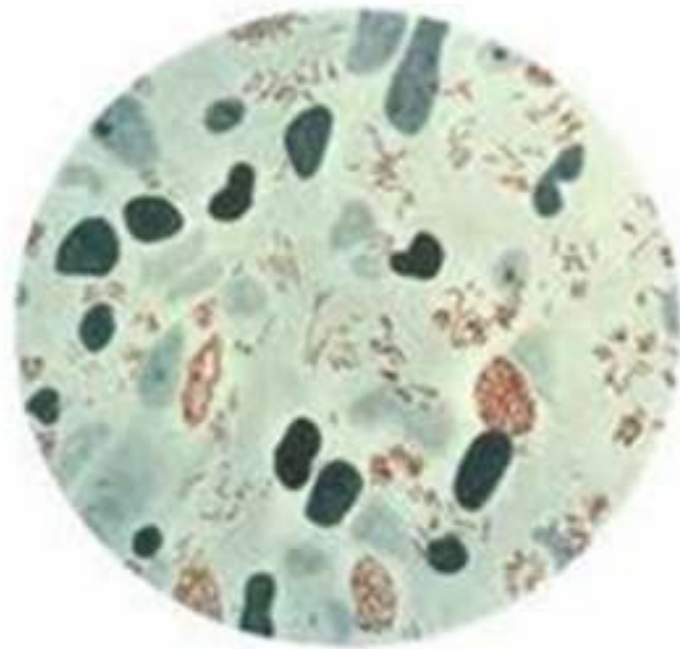


- 1847, **Denielssen și Boech** – first clinical description
- 1873, **Armauer Hansen** – first microbiological description.

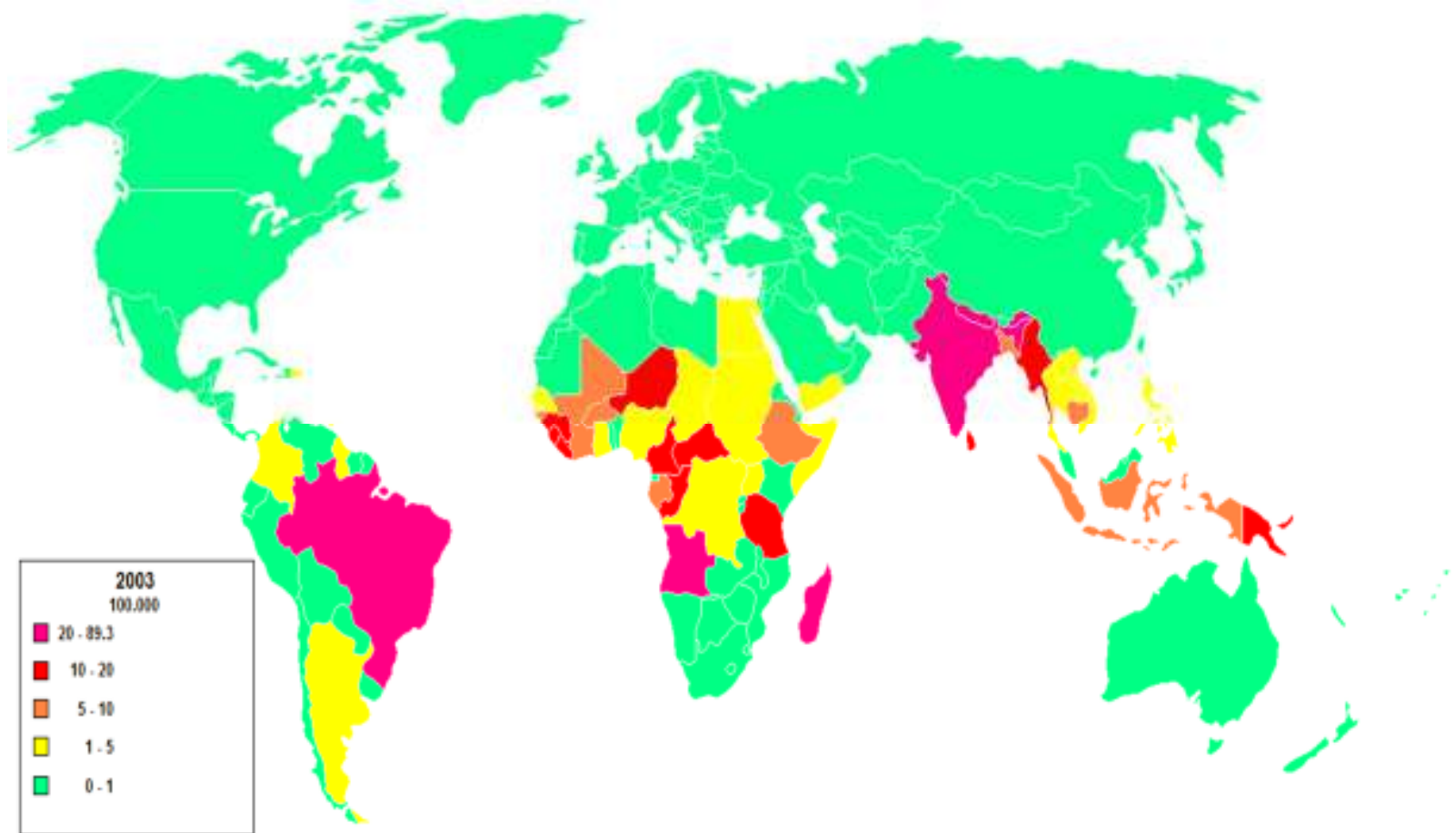


# Etiology

- *M. leprae* is a slender, straight, or slightly curved, acid-fast rod, about 3-5 micrometers
- The organism cannot be cultured in vitro



## RĂSPÂNDIREA LEPREI PE GLOB 2003



- După datele OMS, la începutul anilor 80 în lume erau înregistrate aproximativ 14 mln cazuri de lepră.
- Având în vedere eficacitatea tratamentului combinat, s-a decis scoaterea de la evidență a pacienților tratați timp de 6 – 24 luni (în dependență de formă).
- Astfel în prezent anual sunt înregistrate cca. 1,8 mln. de cazuri în tratament și 500-700 mii cazuri noi.
- Numărul bolnavilor invalidizați după lepră constituie cca. 2 mln (OMS-1995)
- Boala are un caracter de răspândire endemic, incluzând 91 de țări din lume și mai ales țările tropicale și subtropicale, sudul Asiei și Extremul Orient, Africa, America Centrală.

# Leprosy Classification (clinicopathologic)

- Tuberculoid (TL): localized skin involvement and/or peripheral nerve involvement; few organisms are present in the skin biopsies.
- Lepromatous (LL): generalized involvement including skin, upper respiratory mucous membrane, the reticuloendothelial system, adrenal glands, and testes; many bacilli are present in tissue.
- Borderline (dimorphic) (BB): has features of both tuberculoid and lepromatous leprosy; usually many bacilli are present; varied skin lesions – macules, plaques; progresses to TL or regresses to LL.
- Indeterminate and transitional forms.

# Transmission

- Mode of transmission is uncertain; however, human-to-human transmission is the norm
- The main source is the individuals with multibacillary-type infection, shedding several millions of bacilli per day in nasal and upper respiratory tract
- Portals of entry include ingestion of food and drink, inoculation into or through skin (bites, scratches, tattoos, small wounds), or inhalation into nasal passages or lungs.

# Dasypus novemcinctus



# Surse naturale de M.leprae

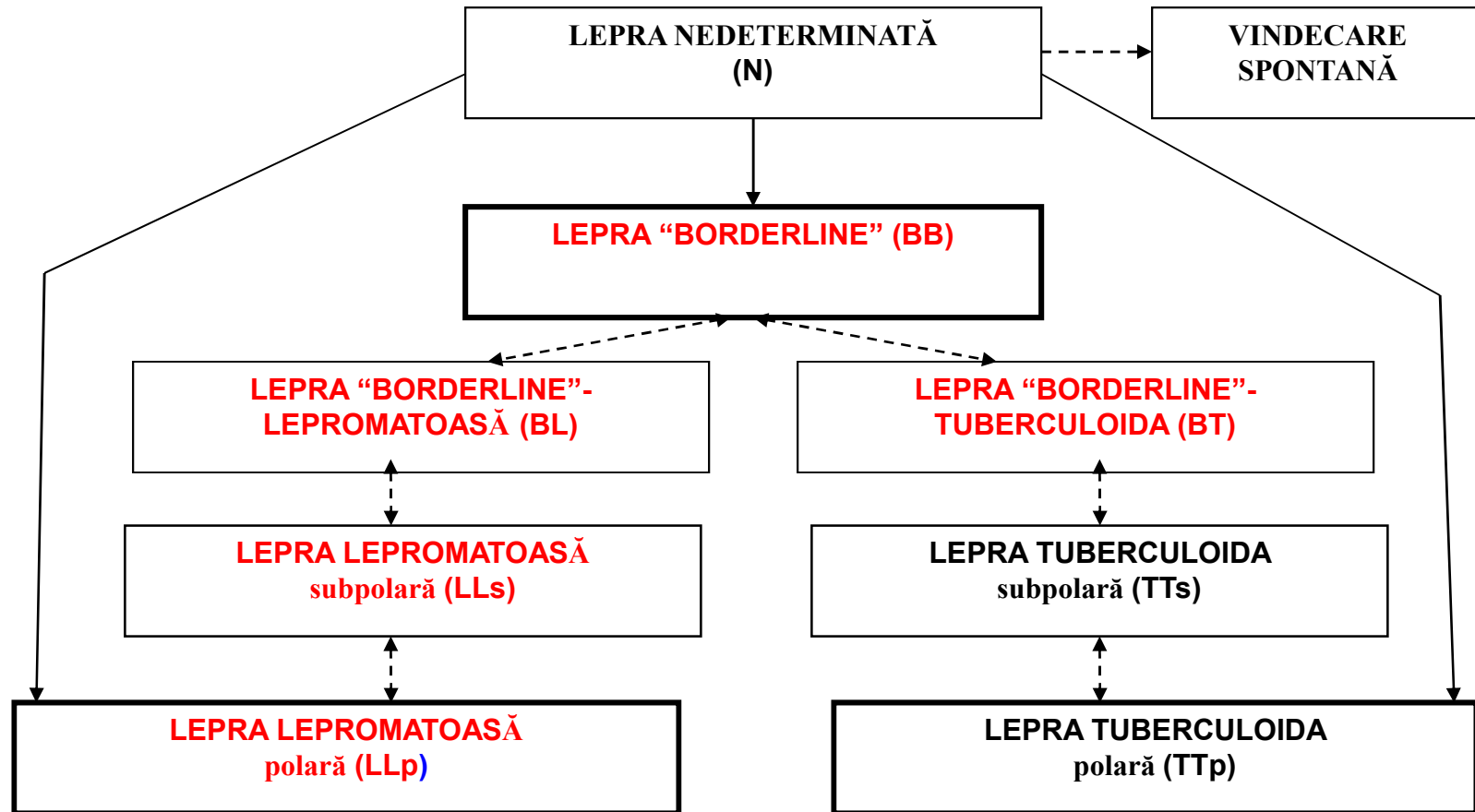


- Naturally occurring infection also has been reported in non-human primates including the African chimpanzee, sooty mangabey, and cynomolgus macaque, as well as in armadillos

# Pathogenesis

- The clinical spectrum of leprosy depends exclusively on variable limitations in the host's capability to develop effective cell-mediated immunity to *M.leprae*.
- The organism is capable of invading and multiplying in peripheral nerves and infecting and surviving in endothelial and phagocytic cells in many organs.
- Clinical expression of leprosy is the development of a granuloma.
- The granulomatous spectrum of leprosy consists of a high-resistance tuberculoid pole (TT), a low or absent-resistance lepromatous pole (LL), a dimorphic or borderline region (BB) and two intermediary regions: borderline lepromatous (BL) and borderline tuberculoid (BT).
- In order of decreasing resistance: TT>BT>BB>BL>LL.

# Leprosy classification (Ridley & Jopling)





### CLASSIFICATION OF LEPROSY

| Clinical findings       | LL  | BL                                      | BB  | BT   | TT                                       | I                            |
|-------------------------|---|---|---|--|--|------------------------------|
| Type of lesions         | Macules, papules, nodules, diffuse infiltration             | Macules, papules, plaques, infiltration | Plaques and domeshaped, punched-out lesions | Infiltrated plaques  | Infiltrated plaques, often hypopigmented | Macules, often hypopigmented |
| Number                  | Numerous  | Many                                    | Many  | Single, usually with satellite lesions, or more than 5 lesions | One or few (up to 5) lesions             | One or few                   |
| Distribution            | Symmetric   | Tendency to symmetry                    | Evident asymmetry                           | Asymmetric   | Localized, asymmetric                    | Variable                     |
| Definition              | Vague, difficult to distinguish normal versus affected skin | Less well-defined borders               | Less well-defined borders                   | Well-defined, sharp borders                                    | Well-defined, sharp borders              | Not always defined           |
| Sensation               | Not affected  | Diminished                              | Diminished                                  | Absent   | Absent                                   | Impaired                     |
| Bacilli in skin lesions | Many (globi)  | Many                                    | Many  | Few (1+), if any, detected                                     | None detected                            | Usually none detected        |

*Adapted from A Guide to Leprosy Control, 2nd ed. Geneva: World Health Organization, 1988:27–28. LL, lepromatous leprosy; BL, borderline LL; BB, mid-borderline leprosy; BT, borderline TT; TT, tuberculoid leprosy; I, indeterminate.*

# Immunologic responses

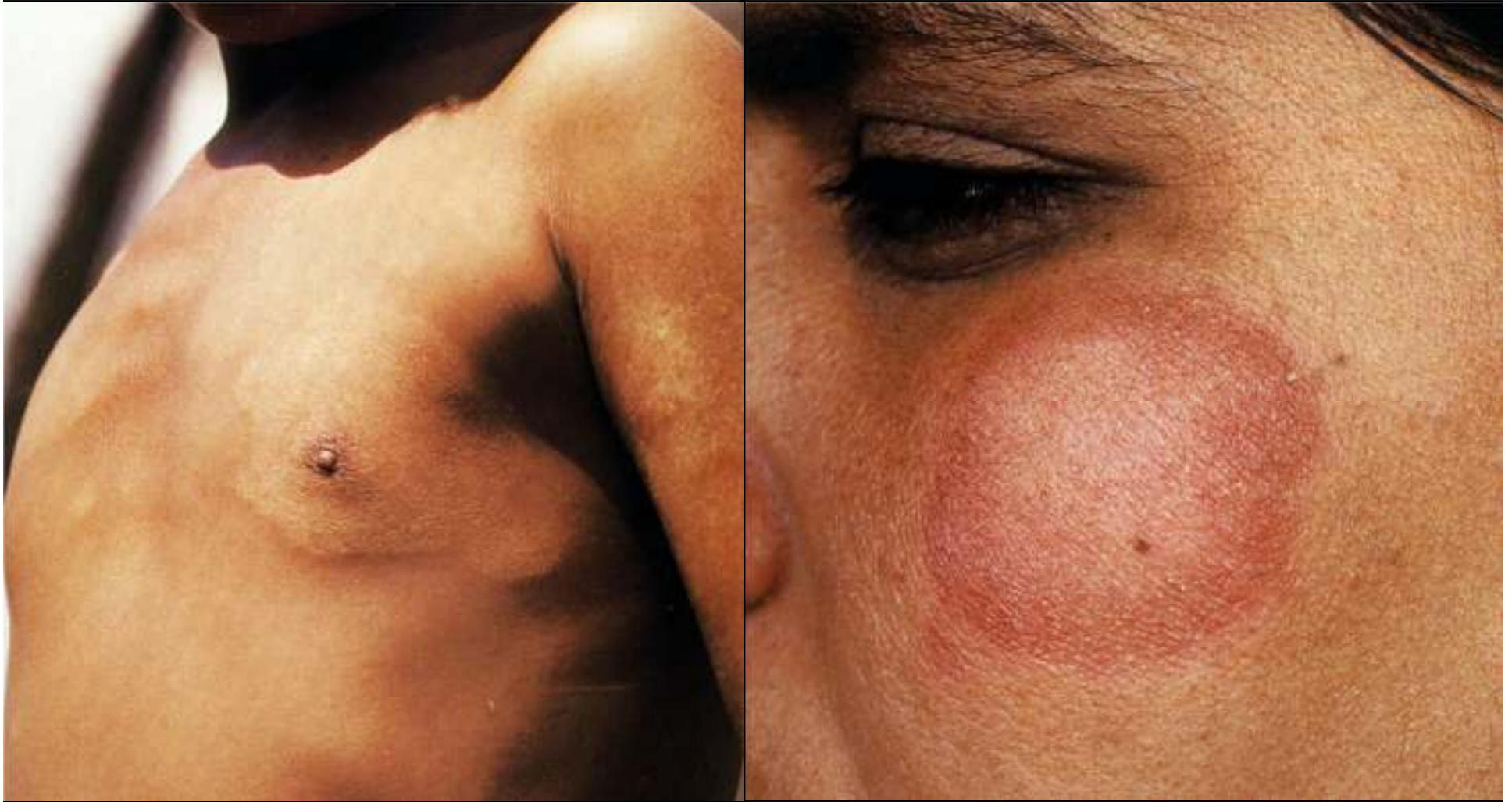Immune responses to *M.leprae* can produce several types of reactions associated with a sudden change in the clinical status:

- Lepra type 1 reactions: individuals with BT and BL develop inflammation within existing skin lesions before therapy or in response to therapy; can be associated with low-grade fever, new multiple small “satellite” maculopapular skin lesions and/or neuritis
- Lepra type 2 reactions: seen in half of LL patients, usually occurring after initiation of antilepromatous therapy, generally within the first 2 years of treatment; massive inflammation with erythema nodosum-like lesions
- Lucio’s reaction: individuals with diffuse LL develop shallow, large polygonal sloughing ulcerations on the legs; the ulcers heal poorly, recur frequently, and may occur in a generalized distribution; generalized Lucio’s reaction is frequently complicated by secondary bacterial infection and sepsis.

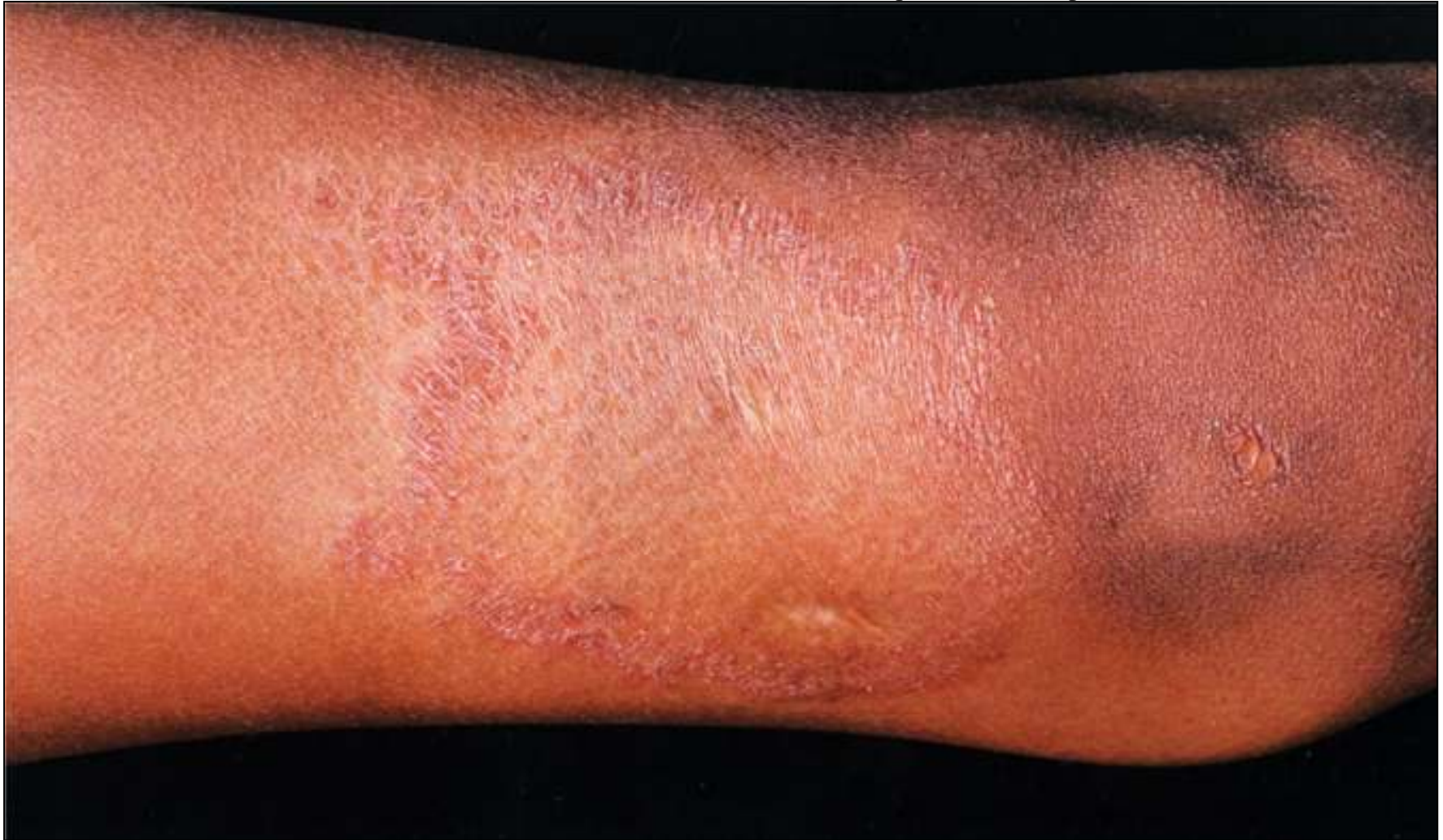# Tuberculoid Leprosy: clinical presentation

- A few well-defined hypo-pigmented anesthetic macules with raised edges and varying in size from a few millimeters to very large lesions covering the entire trunk;
- Erythematous or purple border and hypopigmented center;
- Lesions are sharply defined, raised, often annular and involve any site including face.
- Nerve involvement: may be a thickened nerve on the edge of the lesion; large peripheral nerve enlargement frequent (ulnar).

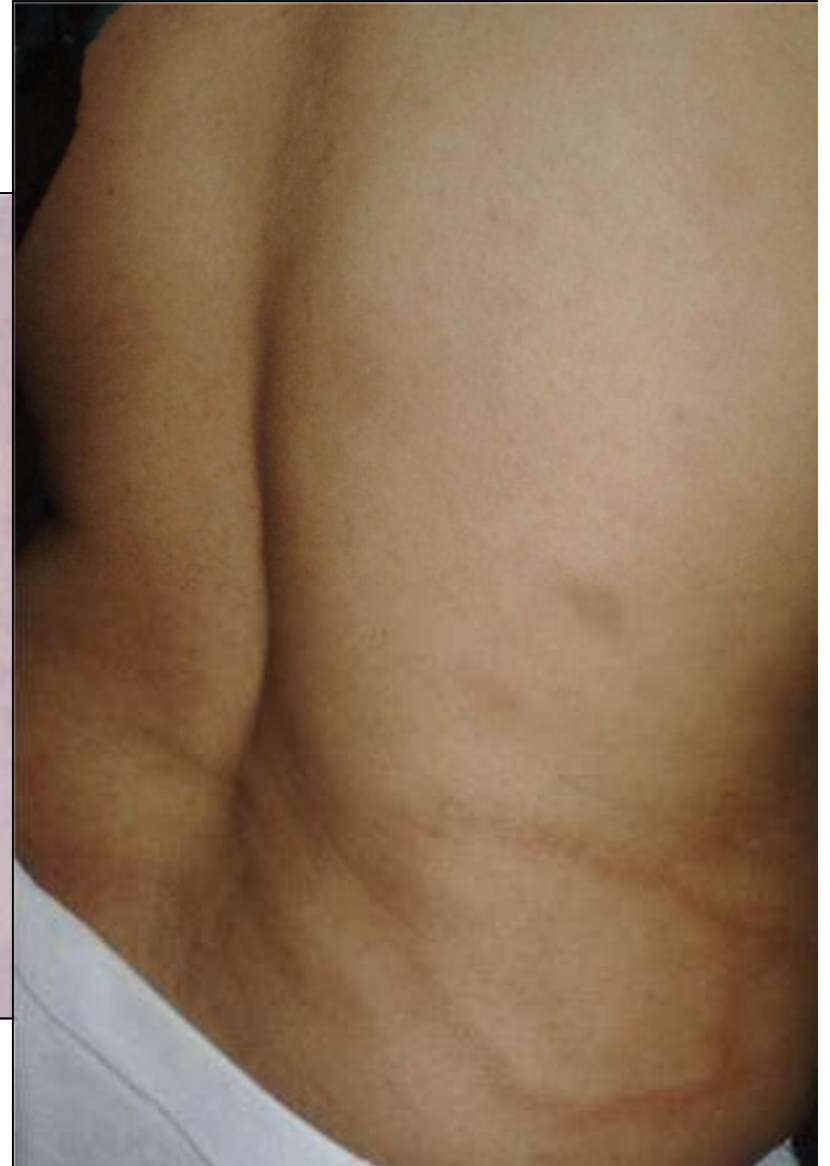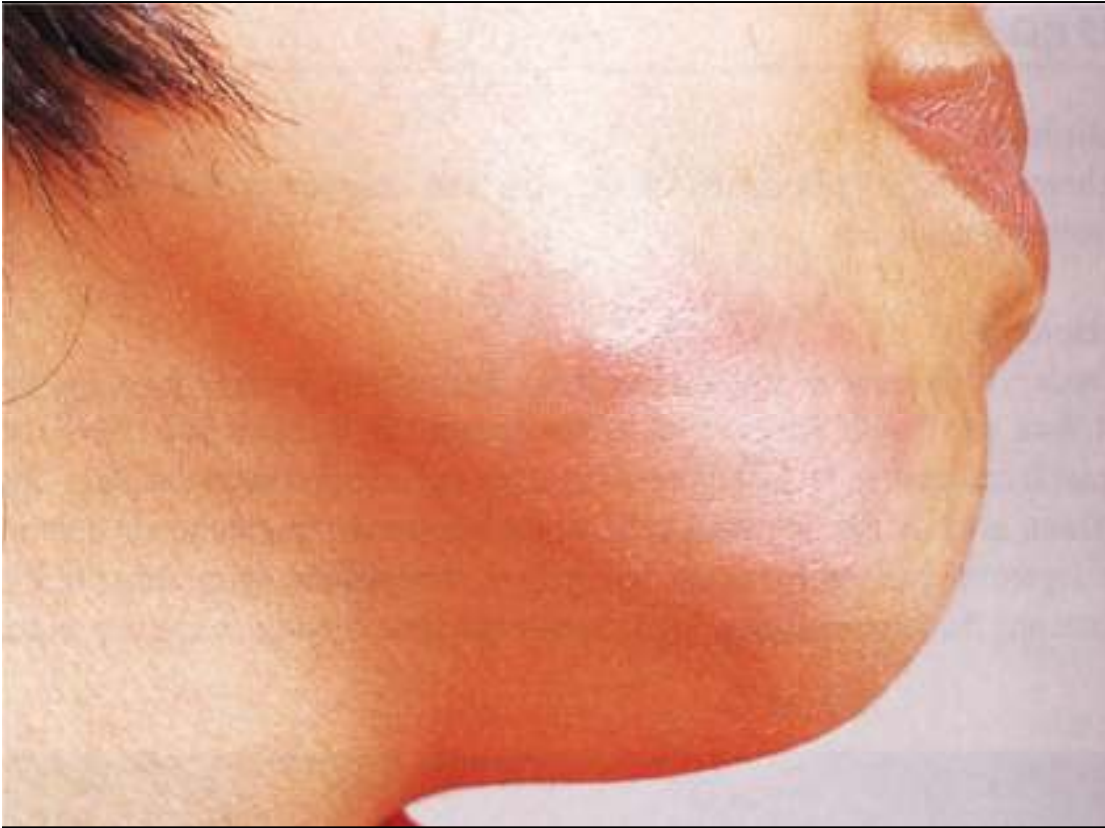# Tuberculoid leprosy



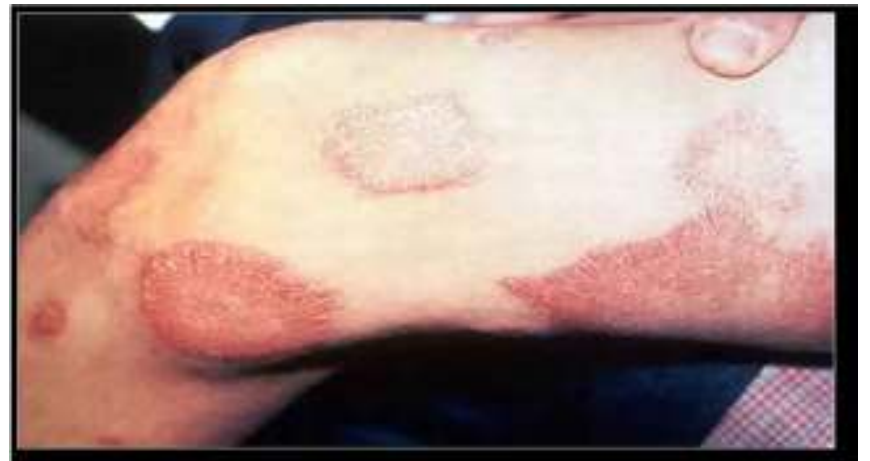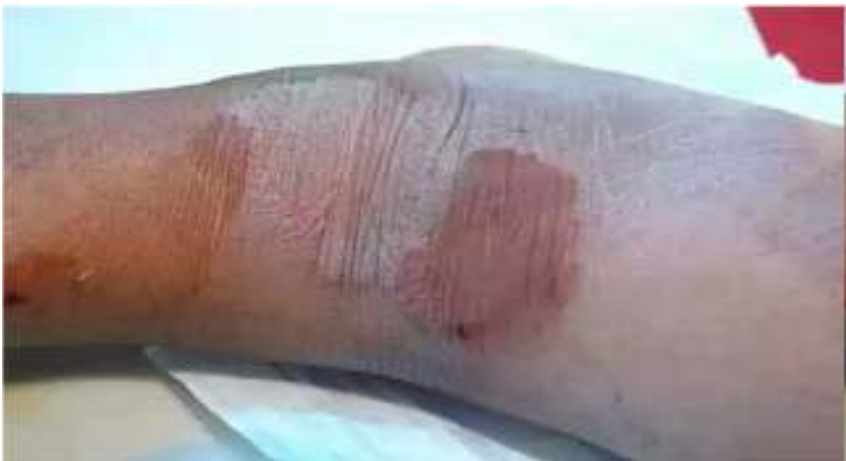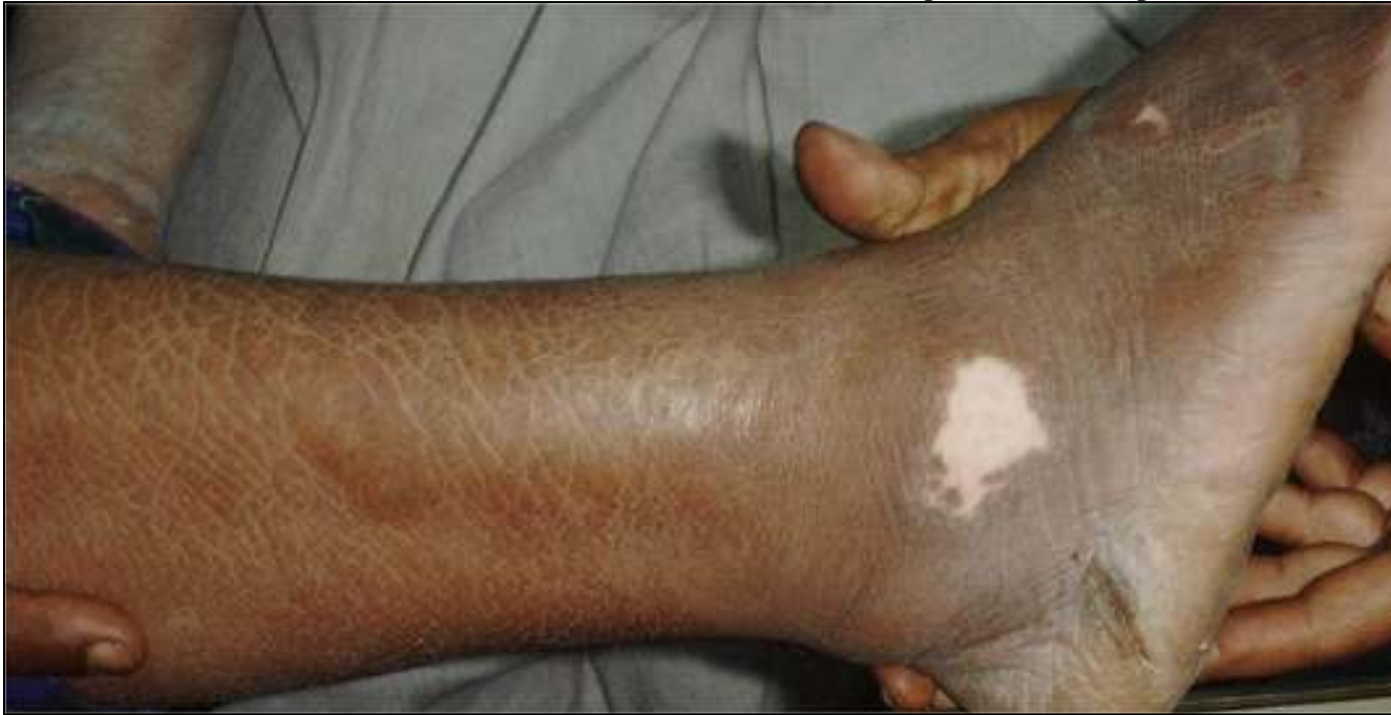# Tuberculoid leprosy



# Tuberculoid leprosy



# Tuberculoid leprosy

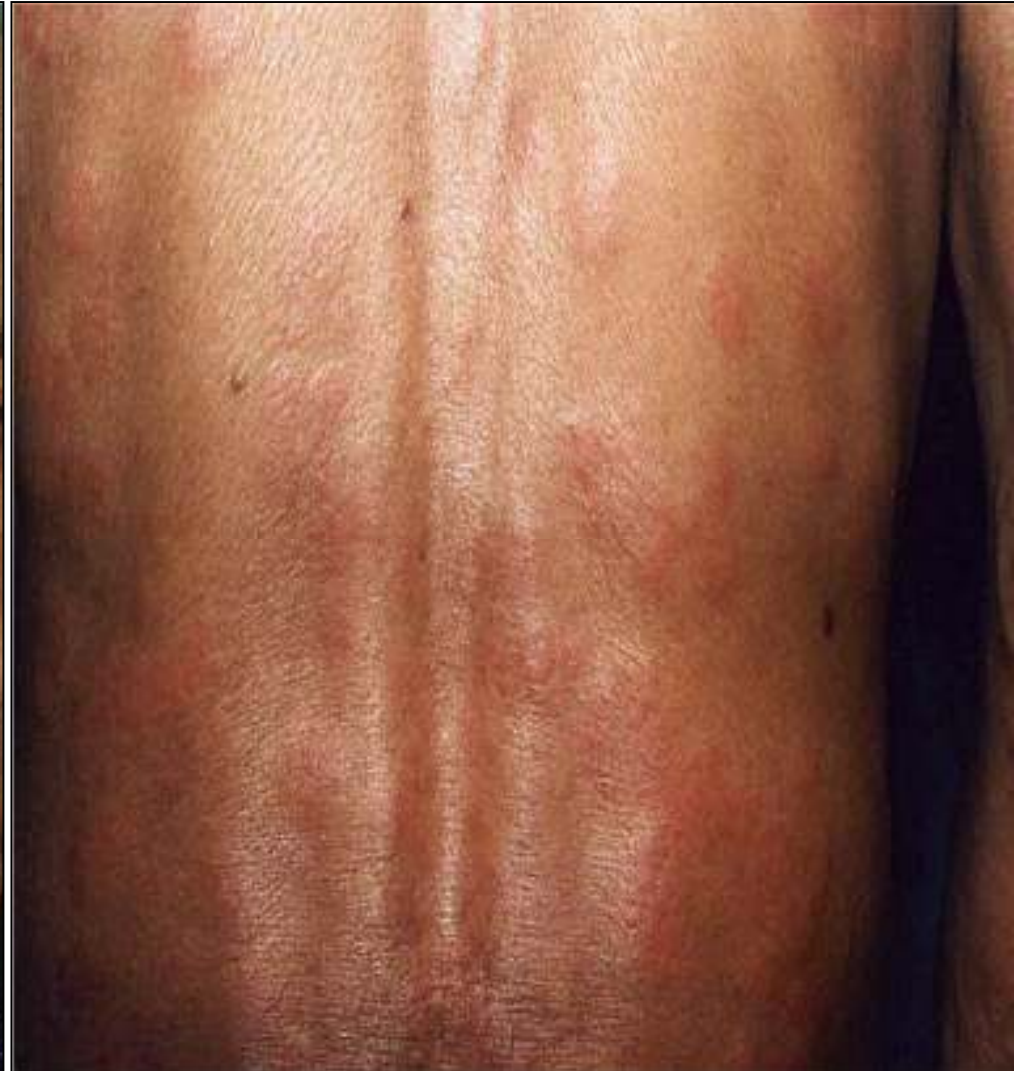

# Lepromatous Leprosy: clinical presentation

- Small erythematous or hypopigmented macules that are anesthetic; later papules, plaques, nodules, and diffuse thickening of the skin, with loss of hair (eyebrows and eyelashes).
- Leonina facies (lion's face) due to thickening, nodules, and plaques distort normal facial features
- Normal skin color or erythematous or slightly hypopigmented
- Distribution of lesions: bilaterally symmetric involving earlobes, face, arms, and buttocks, or less frequently the trunk and lower extremities; tongue involvement with nodules, plaques and fissures.
- Eye involvement: the anterior chamber can be invaded with resultant glaucoma and cataract formation; corneal damage, sensory neuropathy and muscle paralysis can occur
- Testes involvement: resultant hypogonadism.



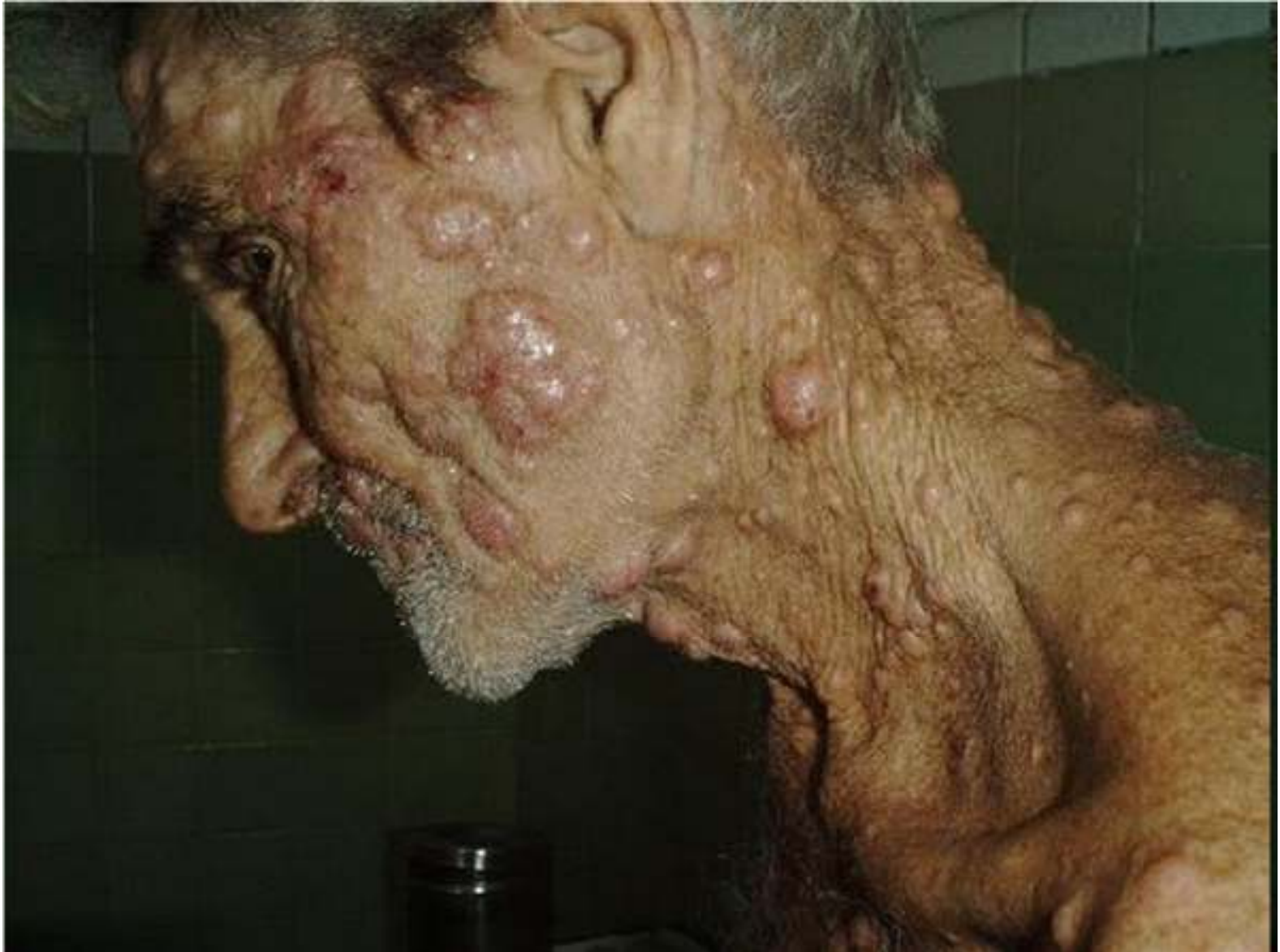# Lepromatous leprosy



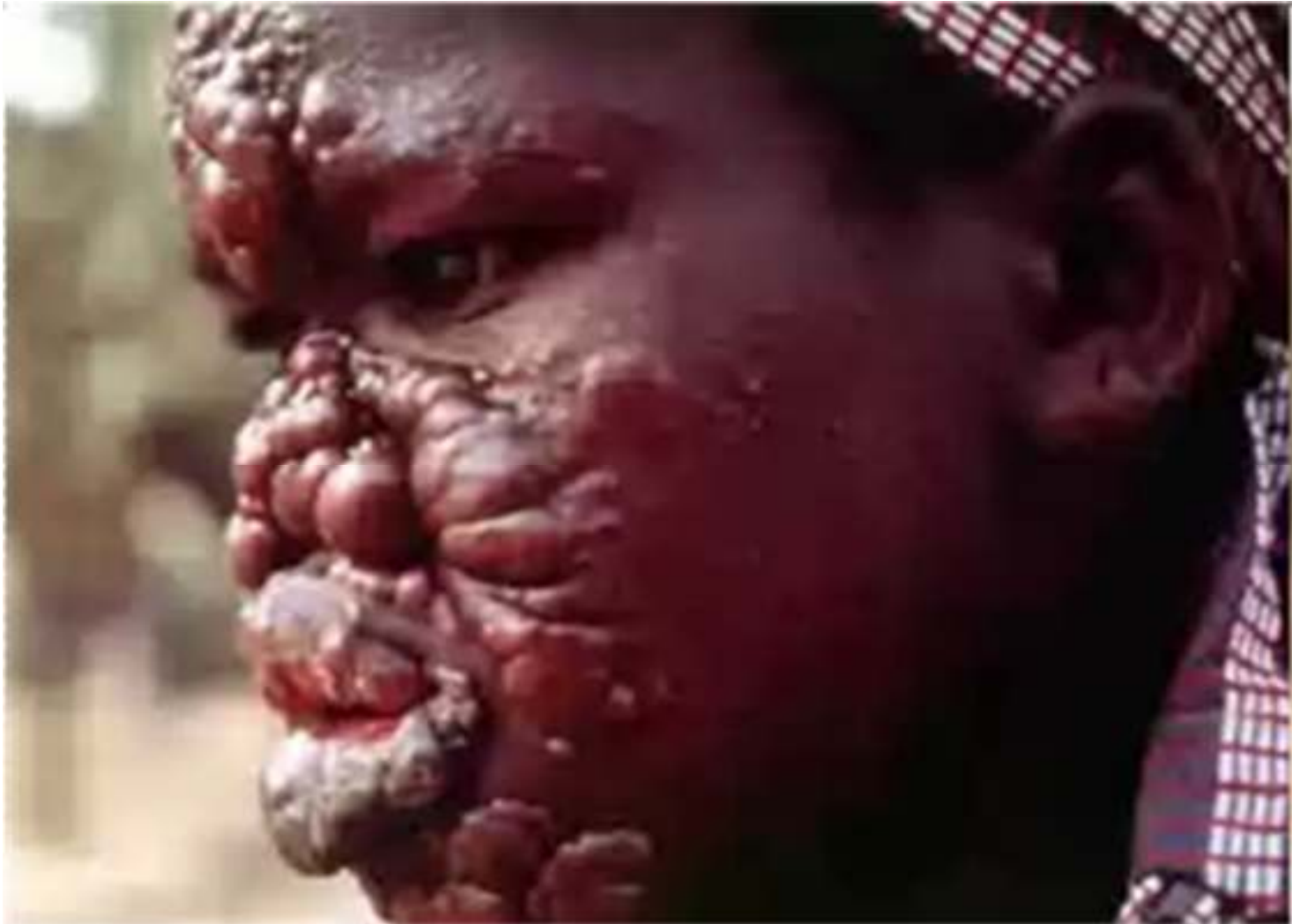# Lepromatous leprosy



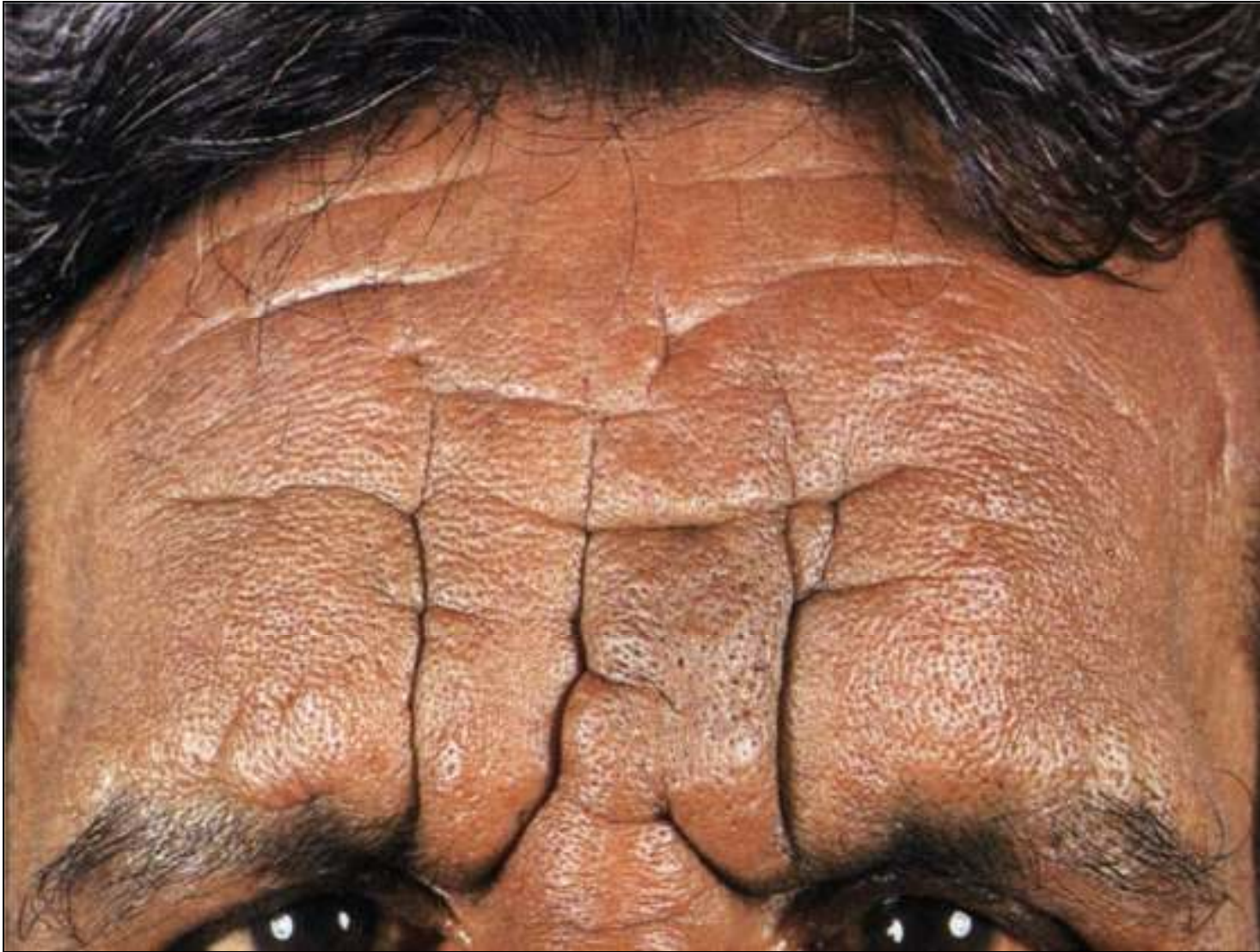# Lepromatous leprosy



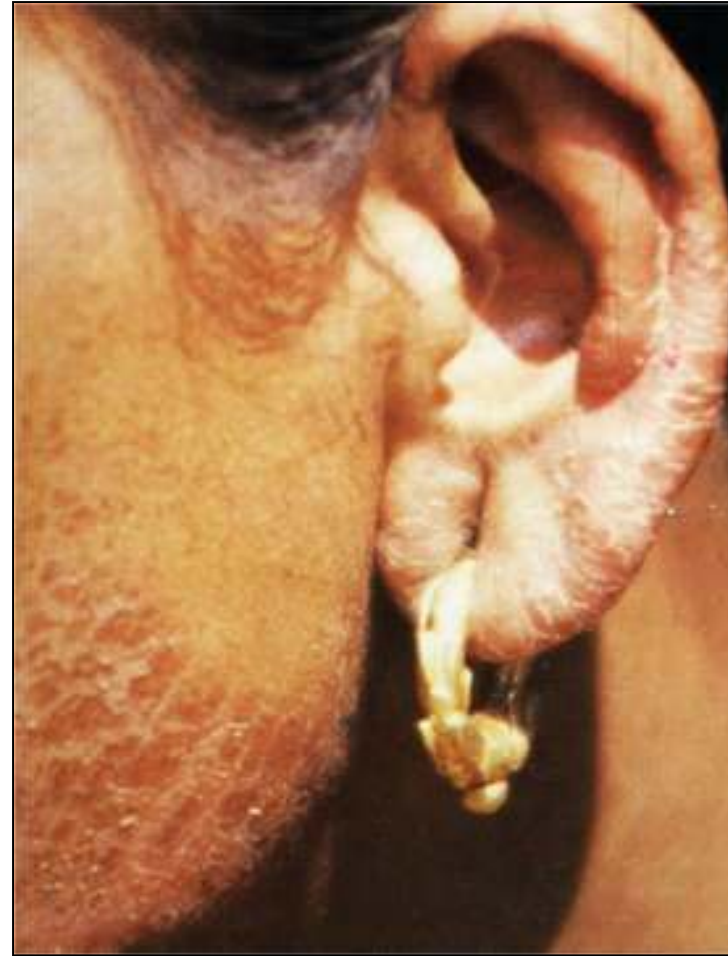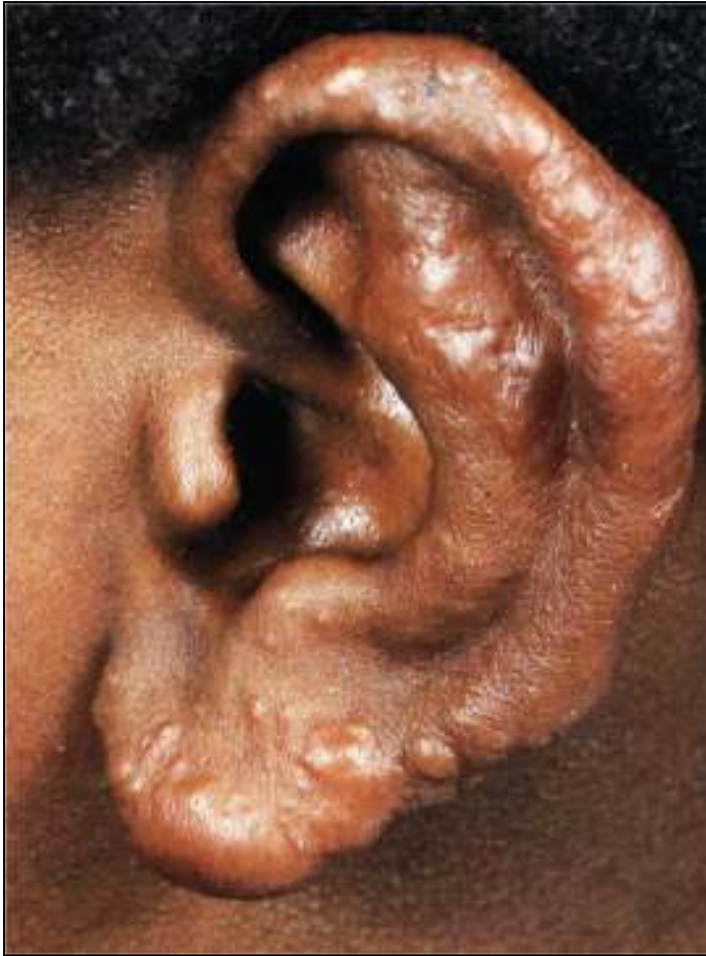# Lepromatous leprosy: leonine face

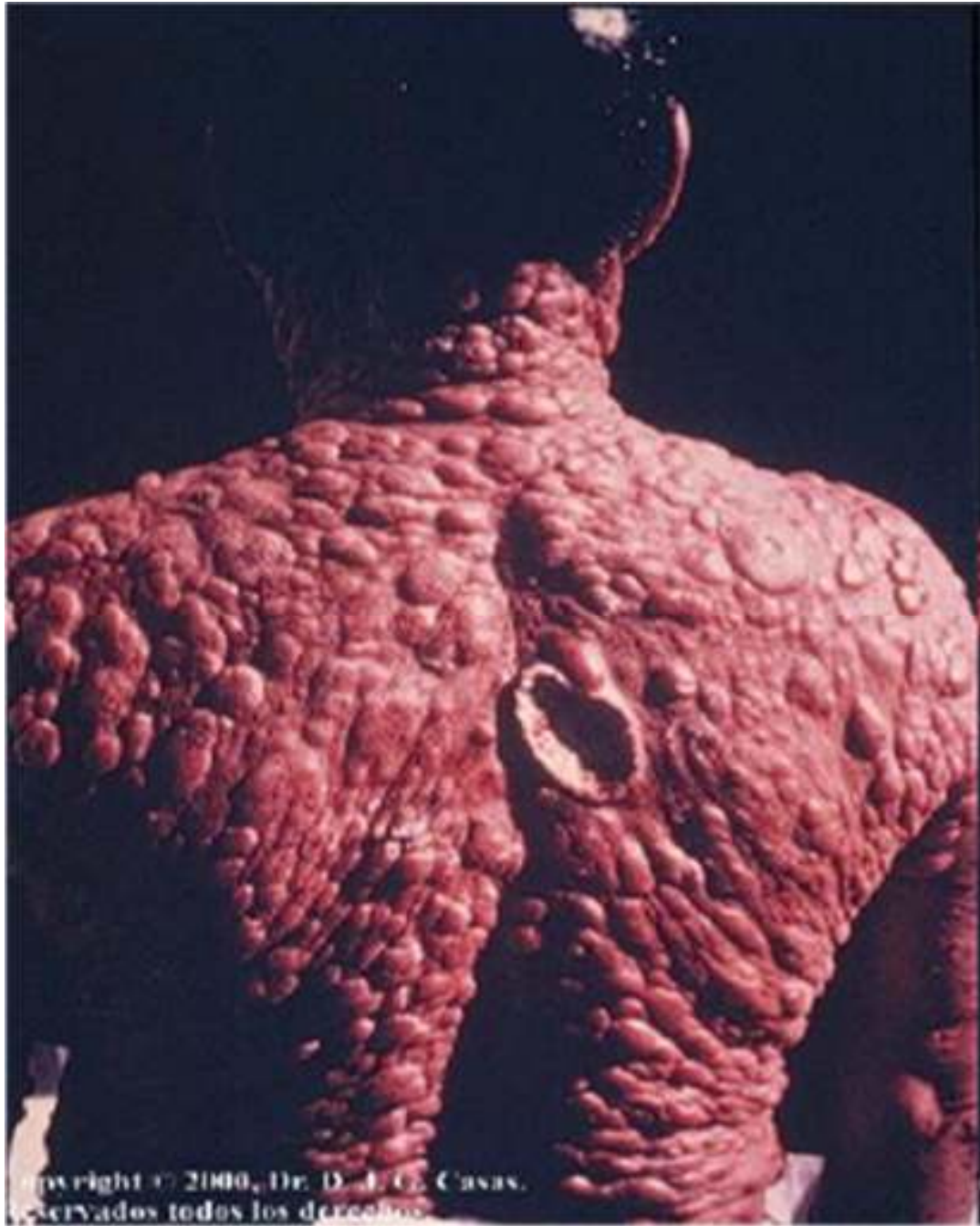


# Lepromatous leprosy



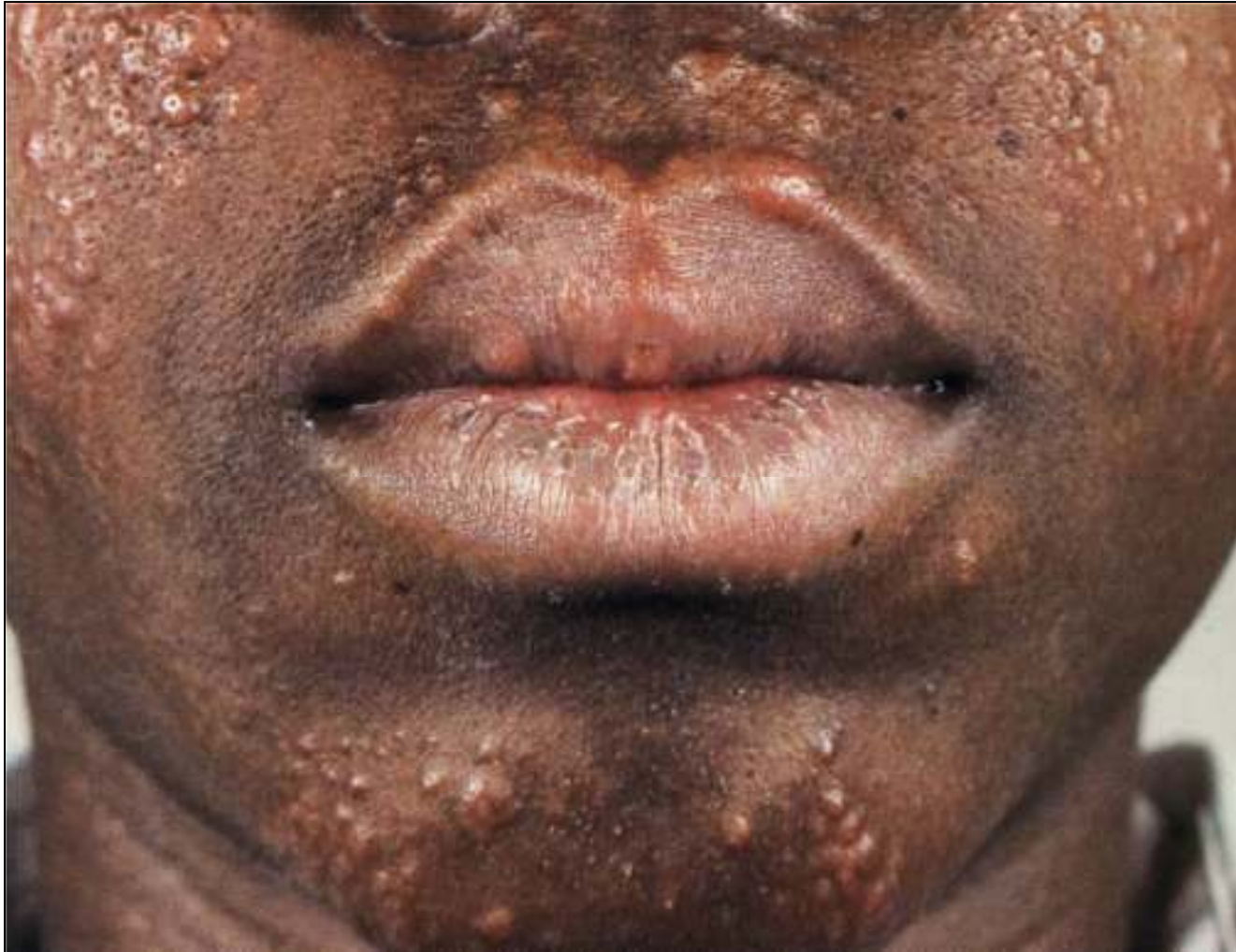# LEPRA LEPROMATOASĂ





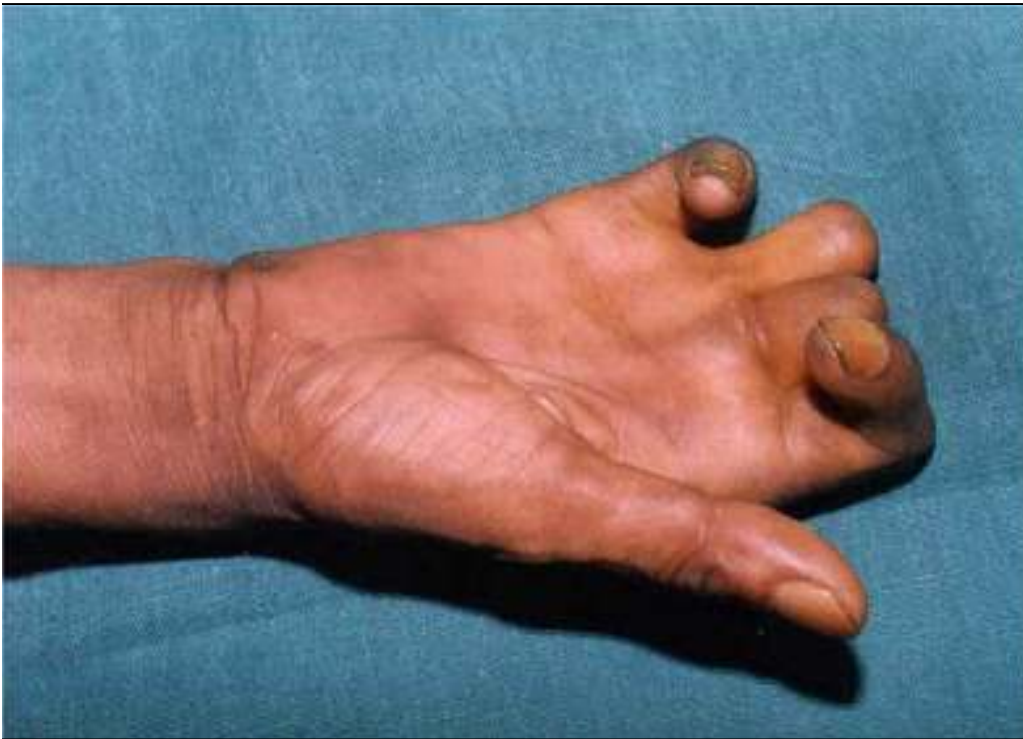Treptat leproamele se rămolesc și exulcerează, formând ulcerații cu fundul murdar și marginile neregulate, care au tendință lentă spre cicatrizare.

# Lepromatous leprosy

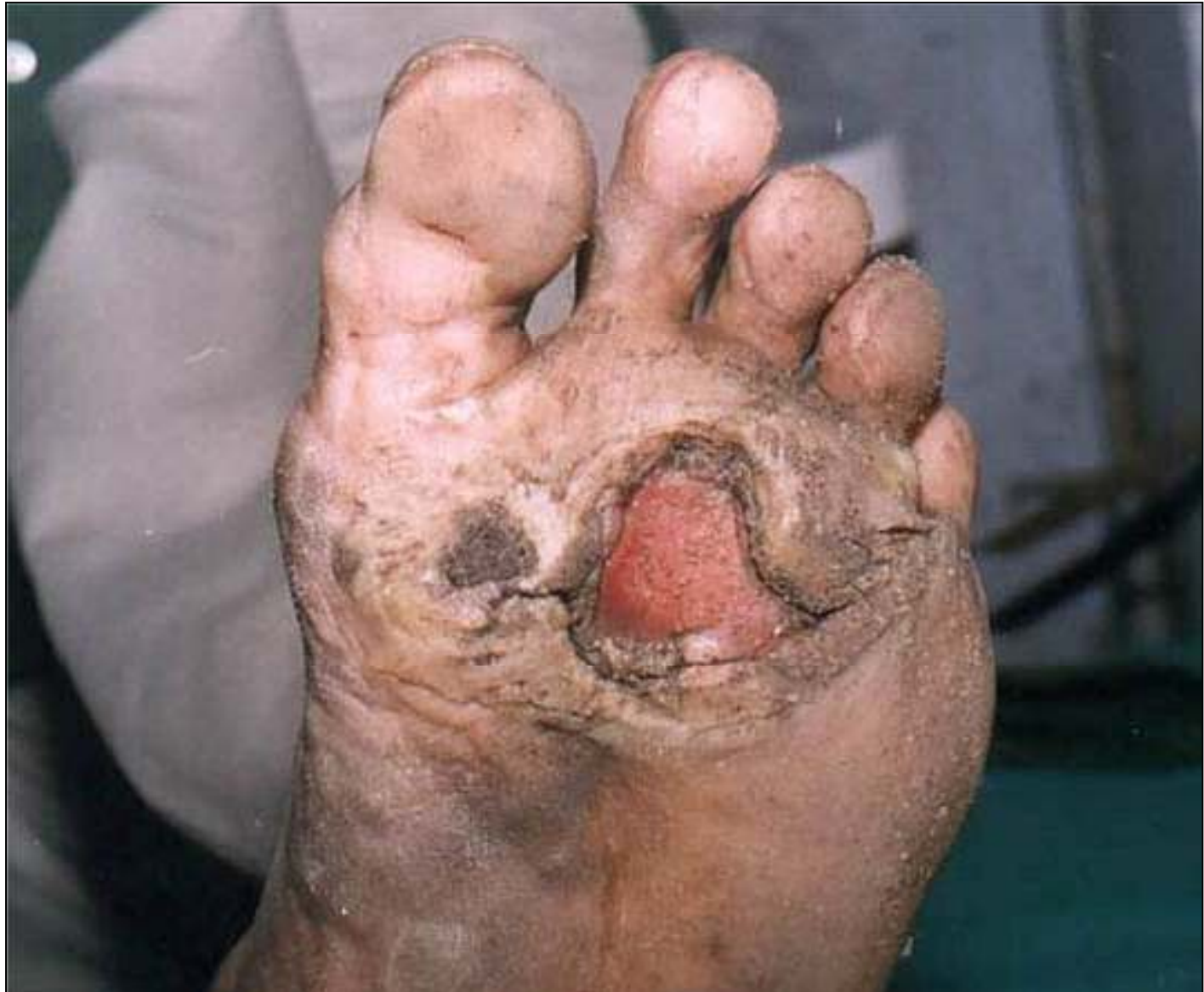



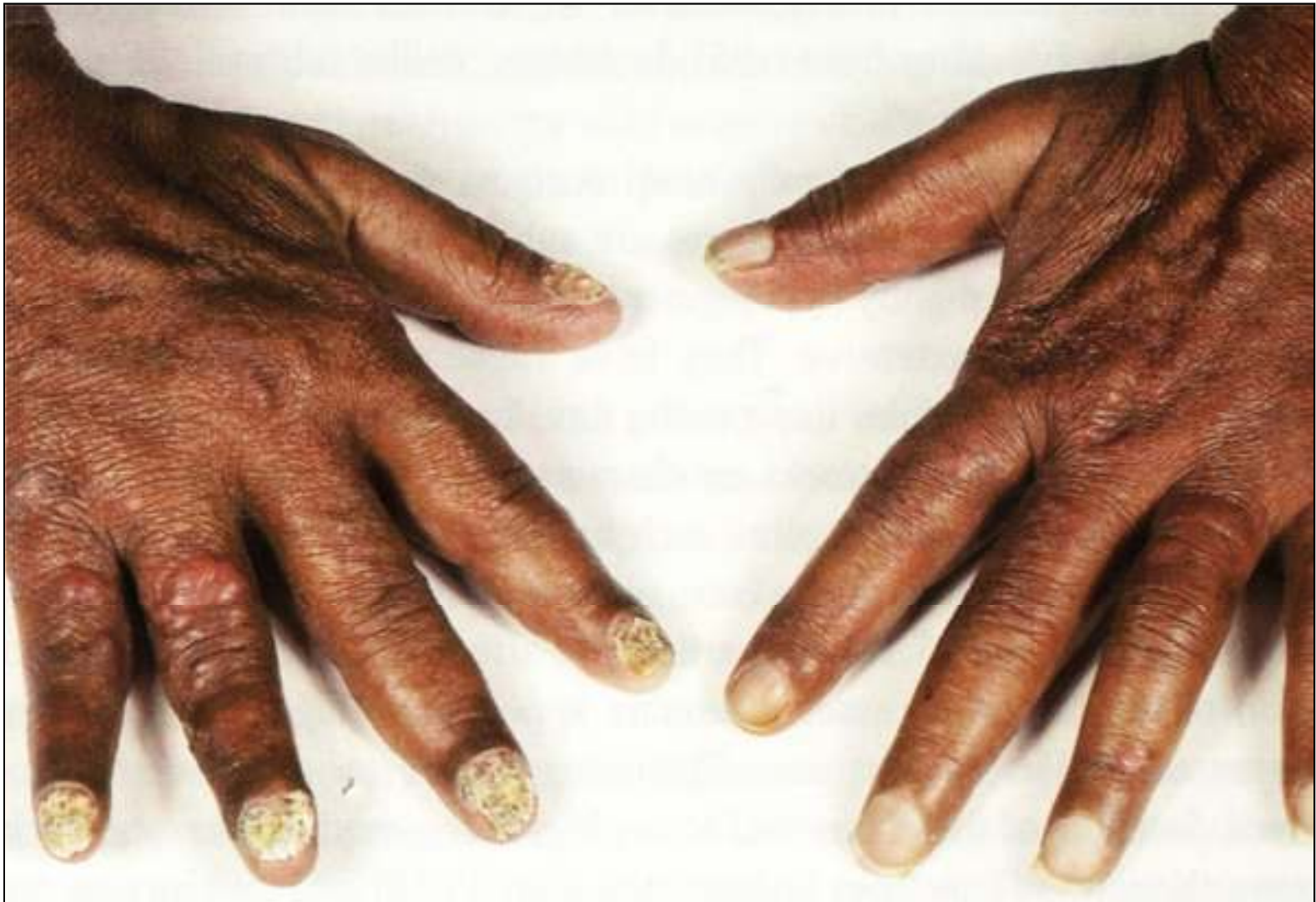# Lepromatous leprosy: mutilations

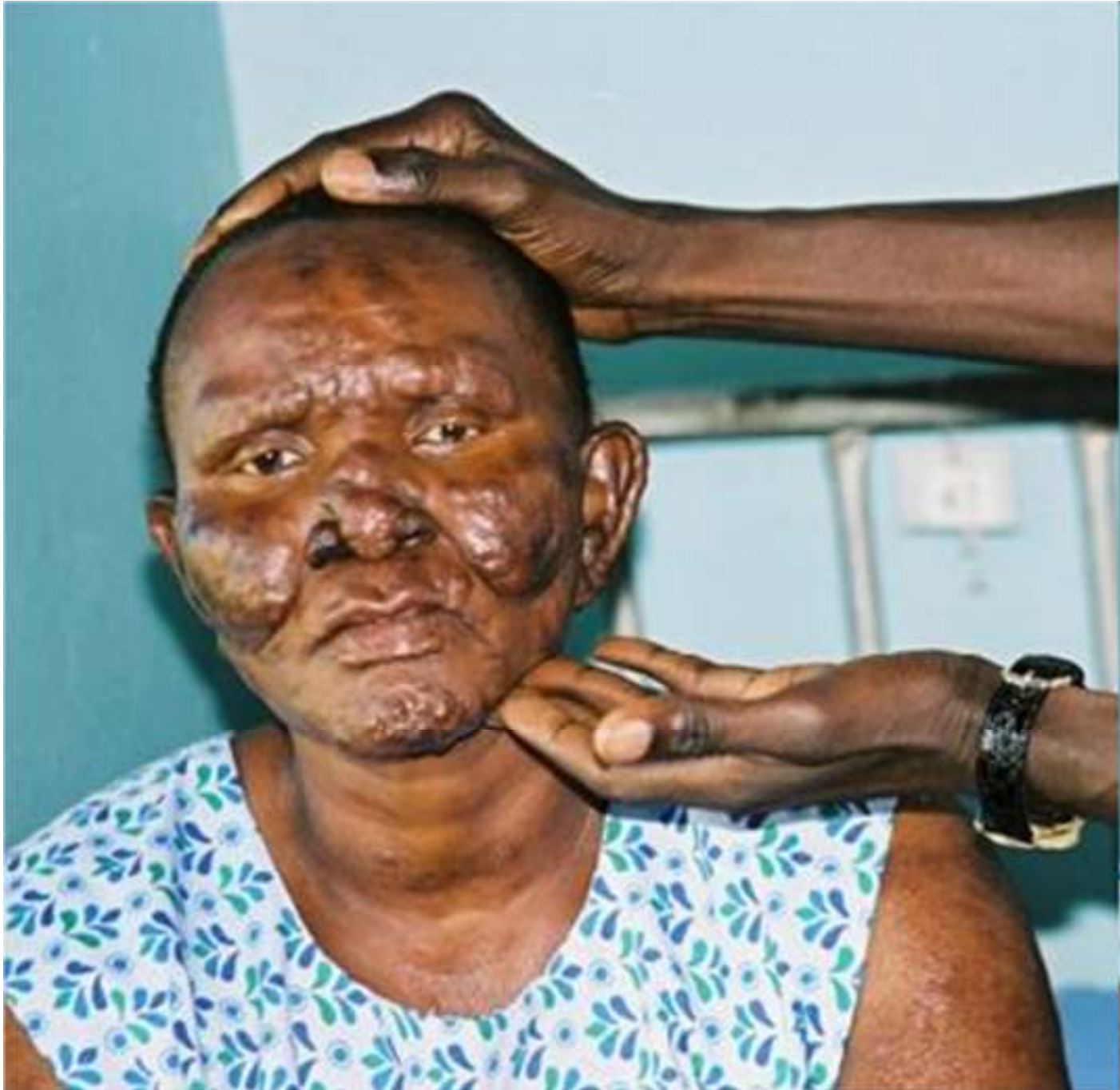

**Lepromatous leprosy:  
ulcers due to loss of sensation**



# Lepromatous leprosy





**Lepromatous leprosy**

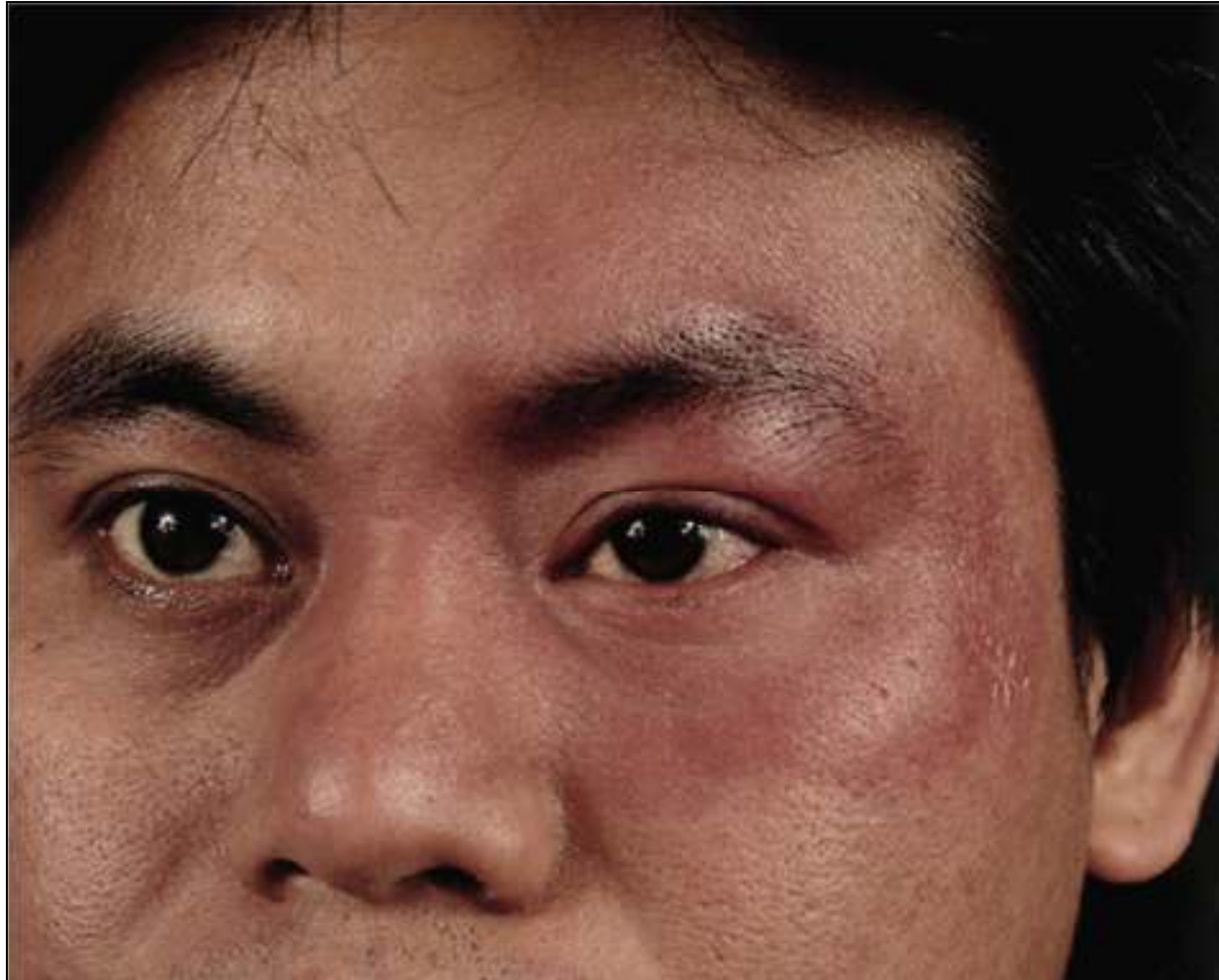# BULB-END PROBE (POSPELOV SIGN)



# Borderline Leprosy: clinical presentation

- Lesions are intermediate between tuberculoid and lepromatous and comprised of macules, papules, and plaques
- Anesthesia and decreased sweating are prominent in the lesions
- Reactional phenomenon:
  - lepra type 1 reaction – skin lesions become acutely inflamed associated with edema and pain; may ulcerate; edema most severe on face, hands, and feet
  - lepra type 2 reaction – present as painful red skin nodules; lesions form abscesses or ulcerate; lesions occur most commonly on face and extensor limbs.
  - Lucio's reaction – presents as irregularly shaped erythematous plaques; lesions may resolve spontaneously or undergo necrosis with ulceration.

# LEPRA BORDERLINE



# Complications

- Contractures and trophic changes in the hands and feet
- Secondary amyloidosis with renal failure
- Lepra type 2 reactions may be complicated by uveitis, dactylitis, arthritis, neuritis, lymphadenitis, myositis, orchitis
- Lucio's reaction: vasculitis with subsequent infarction



## 3 mainstays of leprosy diagnosis

- Cutaneous anesthesia: using a wisp of cotton to demonstrate loss of light touch; in TL and BL within the center of the lesion, while in LL occurs first in fingers and toes;
- Nerve enlargement: in TL and BL occurs within or adjacent to specific skin lesions, while in LL large peripheral nerves can be palpated (posterior auricular nerve, ulnar nerve, etc.)
- The demonstration of *M.leprae* in the skin: accomplished by a “slit skin smear)

# Laboratory examinations

- Slit-skin smears: a small incision is made; the site then scraped to obtain tissue fluid from which a smear is made and examined after Ziehl-Neelsen staining; specimens are usually obtained from both earlobes and two other active lesions
- Nasal smears or scrapings
- Culture: *M.leprae* has not been cultured in vitro; routine bacterial cultures to rule out secondary infection
- PCR: *M.leprae* DNA detected by this technique makes the diagnosis of early paucibacillary leprosy and identifies the germs after the treatment
- Dermatopathology: TL shows epithelioid cell granulomas forming around dermal nerves and acid-fast bacilli are sparse or absent; LL shows an extensive cellular infiltrate separated from the epidermis by a narrow zone of normal collagen, skin appendages are destroyed, macrophages are filled with *M.leprae*, having abundant foamy cytoplasm (lepra Virchow cells)
- Lepromin skin test: an intradermal injection of 0.1 ml of lepromin is read at 48 hours for erythema (Fernandez reaction) or at 3-4 weeks for a papule or nodule (Mitsuda reaction); in TL – strongly positive reaction, while in BL and LL is usually negative.

# Antilepromatous Therapy (paucibacillary disease: TT and BT)

Minimum 6 months treatment duration:

- Rifampin 600 mg / month
- Dapsone 100 mg / day

Post-treatment follow-up duration:

- minimum of 2 years with clinical exams at least every 12 months

# Antilepromatous Therapy (multibacillary disease: LL, BL and BB)

Minimum of 2 years treatment duration:

- Rifampin 600 mg / month
- Clofazimine, 300 mg / month
- Dapsone 100 mg / day
- Clofazimine, 50 mg / day

Post-treatment follow-up duration:

- minimum of 5 years with clinical and bacteriological exams at least every 12 months

# MDT Regimens

**It is crucial  
that patients understand  
which drugs they have  
to take once a month and which  
every day.**

Each blister pack contains treatment for 4 weeks.



PB adult blister pack

### PB adult treatment:

- Once a month: Day 1
    - 2 capsules of rifampicin (300 mg X 2)
    - 1 tablet of dapsone (100 mg)
  - Once a day: Days 2-28
    - 1 tablet of dapsone (100 mg)
- Full course: 6 blister packs



PB child blister pack

### PB child treatment (10-14 years):

- Once a month: Day 1
    - 2 capsules of rifampicin (300 mg+150 mg)
    - 1 tablet of dapsone (50 mg)
  - Once a day: Days 2-28
    - 1 tablet of dapsone (50 mg)
- Full course: 6 blister packs

For children younger than 10, the dose must be adjusted according to body weight.



MB adult blister pack

### MB adult treatment:

- Once a month: Day 1
    - 2 capsules of rifampicin (300 mg X 2)
    - 3 capsules of clofazimine (100mg X 3)
    - 1 tablet of dapsone (100 mg)
  - Once a day: Days 2-28
    - 1 capsule of clofazimine (50 mg)
    - 1 tablet of dapsone (100 mg)
- Full course: 12 blister packs



MB child blister pack

### MB child treatment (10-14 years):

- Once a month: Day 1
    - 2 capsules of rifampicin (300 mg+150 mg)
    - 3 capsules of clofazimine (50 mg X 3)
    - 1 tablet of dapsone (50 mg)
  - Once a day: Days 2-28
    - 1 capsule of clofazimine every other day (50 mg)
    - 1 tablet of dapsone (50 mg)
- Full course: 12 blister packs

For children younger than 10, the dose must be adjusted according to body weight.